




3 5864

UNDP/WORLD BANK/WHO SPECIAL PROGRAMME FOR
 RESEARCH AND TRAINING IN TROPICAL DISEASES

1 - 4 October 1991, Cairo, Egypt



MEETING ON ULTRASONOGRAPHY IN SCHISTOSOMIASIS
 PROPOSAL FOR A PRACTICAL GUIDE TO THE STANDARDIZED USE OF
 ULTRASOUND IN THE ASSESSMENT OF PATHOLOGICAL CHANGES

CONTENTS

	<u>Page</u>
1. INTRODUCTION.....	2
2. STANDARD INVESTIGATIONS.....	2
3. ADDITIONAL INVESTIGATIONS.....	3
4. NORMAL VARIATION.....	3
5. DIAGNOSIS AND PROGNOSIS.....	3
6. OBSERVER VARIATION AND QUALITY CONTROL	4
7. GEOGRAPHICAL VARIATION	5
8. RELATION TO OTHER METHODS OF EVALUATION.....	5
9. CONCLUSIONS.....	5
10. REFERENCES.....	5
11. LIST OF PARTICIPANTS.....	6
ANNEX A. <i>Schistosoma mansoni</i> investigations	
Specifications	7
Record Sheets	12
ANNEX B. <i>S. haematobium</i> investigations	
Specifications	15
Record Sheets	21
ANNEX C. <i>S. japonicum</i> investigations	
Specifications	25
Record Sheets	30

This report contains the collective views of an International group of experts convened by the UNDP/WORLD BANK/ WHO SPECIAL PROGRAMME FOR RESEARCH AND TRAINING IN TROPICAL DISEASES (TDR). It does not necessarily reflect the views of TDR/WHO. In the interests of rapid communication it has been submitted to only minimal editorial revision. Moreover, any geographical designations used in the report do not imply the expression of any opinion whatsoever on the part of TDR or WHO concerning the legal status of any country, territory, city or area or of its authorities concerning the delimitation of its frontiers or boundaries.

Ce rapport exprime les vues collectives d'un groupe international d'experts réuni par le PROGRAMME SPECIAL PNUD/BANQUE MONDIALE/OMS DE RECHERCHE ET DE FORMATION CONCERNANT LES MALADIES TROPICALES (TDR). Il ne représente pas nécessairement les vues du TDR/OMS et, en vue d'une diffusion accélérée, il n'a pas été l'objet d'une mise en forme particulièrement soignée. En outre, les noms géographiques utilisés dans le présent rapport n'impliquent, de la part du TDR ou de l'OMS, aucune prise de position quant au statut juridique de tel ou tel pays, territoire, ville ou zone, ou de ses autorités, ni quant au tracé de ses frontières.

1. INTRODUCTION

A TDR consultation, cosponsored by the Division of Control of Tropical Diseases (CTD) and the Radiation Medicine (RAD) Unit was held in collaboration with the Swiss Tropical Institute and the Faculty of Medicine, Cairo University, from 1 to 4 October 1990 at the Department of Endemic Medicine, Kasr El-Aini Hospital, Cairo, Egypt. Ultrasonography experts and physicians with a wide experience of application of this technology in schistosomiasis and other tropical diseases discussed studies carried out in different contexts and in different parts of the world. They concluded that comparisons would be facilitated by a standardized methodology.

Schistosomiasis control programmes rely on accurate determinations of prevalence and intensity of disease as well as on correct estimates of the pathology resulting from long-standing infection (1). In the field, morbidity has historically been evaluated clinically since radiology, although valuable in the detailed assessment of this parameter, does not lend itself to large-scale screening operations. Ultrasonography, on the other hand, is a field-applicable, rapid, non-invasive technique which can be used for examining large numbers of people at a relatively low cost per capita. During the last few years, it has been increasingly utilized as an additional tool for detection of pathological lesions and as a means of assessing changes in affected organs following chemotherapy. In contrast to radiology, however, the grading and staging of pathological conditions is still evolving. Because there is no standardized reporting of observations by different investigators in different endemic settings, results are not directly comparable. This current limitation also hampers the evaluation of longitudinal studies.

It was pointed out that clinical and laboratory data play as large a role for the correct diagnosis as does ultrasonography. This issue was only marginally discussed but it was stressed that other diagnostic approaches, particularly urine and stool examinations, should always be obtained and the ultrasound results evaluated in relation to these findings.

While there were opposing opinions on several issues, a consensus was reached on standard examination protocols for each of the three types of schistosomal infection. These basic investigations would include qualitative and quantitative assessments of differentiation between normal and pathological ultrasound patterns. In order to achieve this, careful and thorough training of investigators, as outlined previously (2) would also need to be implemented. It was accepted that unresolved issues could be clarified by collection and comparison of data in standardized protocols and, to this end, a set of diagnostic modules was proposed (Annex A,B,C).

2. STANDARD INVESTIGATIONS

The standard protocols (module 1 in the annexes) were designed so as to obtain the necessary basic information in the limited time (3-5 minutes) usually available for each examination in the field. Studies would benefit from standard positions of the ultrasound probe, particularly in relation to assessments of the size of internal organs. The modules permit the recording of grades assessing the severity of lesions as well as the recording of absolute measurements. The grades represent an attempt to classify the pathology in terms of severity, while the measurements of organ size would also serve to improve longitudinal studies. Both types of record are intended to establish criteria for comparative studies and to facilitate computer analysis. The implementation of these modules in as many field studies as possible would contribute to establishing a body of comparable data.

3. ADDITIONAL INVESTIGATIONS

Potentially useful examinations which could be added to the standard protocols are also included in each annex (module 2). For urinary schistosomiasis, there are actually three additional examinations: one for calcification and fibrosis, one for residual urine measurement and one for liver pathology (Annex B). Although it was felt that the annexes incorporate all important investigations that could be envisaged, special studies might warrant designing additional modules in the future.

4. NORMAL VARIATION

Knowledge of the normal variations in the target organs of uninfected people from the endemic area is vital when judging whether or not a finding is pathological. The correct diagnosis relies on correct measurements, carried out in a standardized way, e.g., with adequate filling of the bladder, standard positions of the ultrasound probe in liver assessment, etc. Since there are insufficient data of this type it was recommended that ultrasonography be applied increasingly for assessment of the appearance, size, texture and internal structures of normal organs. It would be of particular interest to perform such examinations for comparison between:

- (a) different population groups, e.g., by age-group, height, sex, etc.;
- (b) different geographical areas; and
- (c) areas endemic also for other diseases which affect the same organs as schistosomiasis, e.g., malaria.

5. DIAGNOSIS AND PROGNOSIS

Due to their influence on affected organs, certain pathological changes may indicate the probable evolution of morbidity. Standardized, detailed ultrasound observations of these changes might lead to better identification of the stage of the disease and contribute to an improved basis for prognosis.

5.1 Pathognomonic Signs

A list of lesions, typical for chronic infection due to each species, would be useful. The following examples were considered to be clear-cut diagnostic signs:

- (a) in *S. haematobium* infection in certain endemic areas, calcification of the bladder wall;
- (b) in *S. mansoni* infection, periportal thickening; and
- (c) in *S. japonicum* infection, the "fishscale" or "network" liver pattern.

5.2 Liver Pathology in *S. haematobium* Infection

In some areas, liver pathology has been described in schistosomiasis due to *S. haematobium*. Ultrasound findings in the liver, using the criteria established for *S. mansoni* infection, in patients from various geographical areas endemic for urinary schistosomiasis would be of considerable value.

5.3 Assessment of Periportal Thickening

The differentiation between early infection and advanced disease rests on the relationship between the clinical condition and the distortion of the portal vein. It was proposed to investigate if the diagnosis would be facilitated by calculating, either:

- (a) the arithmetic mean of measurements of the external width of three different peripheral portal branches; or
- (b) the ratio of the external width to the internal diameter (lumen) of three different peripheral portal branches for classification of the severity according to grades: $\leq 2 = 0$, $> 2 = 1$.

The first calculation is included in module 1 for infection due to *S. mansoni* and *S. japonicum*. The second is included in module 2 so that the comparison can be made. The same two methods could also be applied to the central portal vein at the *porta hepatis*.

5.4 Staging

Several staging systems have been previously proposed. Since there are geographical differences in the evolution of pathology, a consensus has not been achieved so far. It was recommended to determine the frequency of lesions and whether or not certain lesions appear at the same stage of the disease. If patterns could be identified, it might be possible to use this information in an overall staging classification of the disease.

5.5 Prognostic Signs

The identification of patients in whom the infection is likely to lead to severe symptoms, such as bleeding from oesophageal varices or disability, constitutes an important aim of ultrasound surveys. The positive and negative predictive values of ultrasound readings are largely unknown and extensive research involving longitudinal studies needs to be carried out in order to confirm the hypotheses. Given the limitations in time and resources, focus on key signs is required. From the studies published so far, the following lesions were suggested to predict a severe outcome:

- (a) in *S. haematobium* infection, development of hydronephrosis;
- (b) in *S. mansoni* and *S. japonicum* infections, portal hypertension and oesophageal varices (bleeding risk).

6. OBSERVER VARIATION AND QUALITY CONTROL

Since current scanners generally produce consistent images the equipment used does not often contribute to variant results. The type of equipment should, however, always be clearly described and its reliability in the field should be reported. Further studies are needed regarding variation between different investigators, as well as between different observations by the same investigator at different times. It would also be useful to identify which observations, made with the same technique, are most frequently subject to variation and to investigate how the source of this variation can best be avoided. It was recommended to include measures to quality-control to ensure that observer variation is kept to a minimum. This is, in fact, already practised in some areas, for example, in an Egyptian country-wide programme. It would be particularly important to pay attention to:

- (a) differences in methodology, i.e. in the positioning of the probe, which can have a considerable effect, e.g. on size measurements; and
- (b) differences in interpretation, depending on personal experience.

7. GEOGRAPHICAL VARIATION

There is some evidence that the pathology of infection resulting from the same species of *Schistosoma* varies between different areas and population groups, e.g. in the degree of calcification of the bladder wall in urinary schistosomiasis. Such variations could depend on intra-species variations of the parasite or from behavioural host differences in terms of infection and/or re-infection patterns. Standardized ultrasound protocols in different endemic settings would show whether or not these variations are real and, if so, would help to establish the cause.

8. RELATION TO OTHER METHODS OF EVALUATION

Correlations between ultrasonography and other diagnostic techniques are not always consistent reflecting their different scales of application and the need for mutually agreed standards. Reagent strips for detection of blood in the urine are widely used in urinary schistosomiasis and quantitative parasitological diagnosis requires three standard urine or stool samples to classify the intensity of infections correctly. The latter two techniques are well standardized and the development of ultrasonography in this direction would improve the reliability of the final diagnosis.

9. CONCLUSIONS

The widening use of ultrasonography has improved the potential of diagnostic techniques in schistosomiasis and the availability of portable ultrasound units facilitates large-scale ultrasound investigations in the field. The use of this technique offers a unique possibility of producing reliable records of morbidity and, given the current growth of its application in the field, the scientific community working in this area should be encouraged to use standard protocols as soon as possible. Although the proposed protocols are intended to lead to technical standardization, efforts made so far to establish basic standards in ultrasonography should be seen as tentative. Final agreement would need to await feed-back from use of the proposed protocols and record sheets in the field.

10. REFERENCES

1. The control of Schistosomiasis. Report of a WHO Expert Committee. Technical Report Series 728, WHO, Geneva 1985, pp 81-83.
2. Future use of new imaging technologies in developing countries. Report of a WHO Scientific Group. Technical Report Series 723, WHO, Geneva, 1985, pp. 18-19.
3. Weill, F., Bihr, E., Rohmer, P and Zeltner, F. Hydronéphrose, Lithiase. Chapter 3 in "L'ultrasonographie rénale". Editions Vigot, Paris, 1983, pp 39-50.
4. Lutz, H. and Meudt, R. Manual of Ultrasound. Springer-Verlag, Berlin, Heidelberg, New York, Tokyo, 1982, p 101.

11. LIST OF PARTICIPANTS

ALI, Professor Q.M. College of Medicine, Sultan Qaboos University,
P.O. Box 32485, Al-Khod, Muskat, Sultanate of Oman

ABDEL WAHAB, Professor F. Department of Endemic Medicine, Faculty of Medicine,
Kasr El-Aini Hospital, Cairo University, P.O. Box 1, Manial El Roda,
Cairo, Egypt

CAI, Professor Wei-men. Department of Parasitic Diseases, Institute of
Infectious Diseases, Zhejiang Medical University, Hangzhou, China

CERRI, Dr G.G. Hospital das Clinicas, Faculdade de Medicina da Universidade de
Sao Paulo, Caixa Postal 8091, Sao Paulo, Brazil

DOEHRING-SCHWERDTFEGGER, Dr E. Institut für Medizinische Parasitologie der
Universität Bonn, Postfach 1825, Sigmund-Freud-Strasse 25, D-5300 Bonn 1,
Germany

GHARBI, Professor H.A. Hôpital d'Enfants de Tunis, Service de Radiologie,
Place Bab Saadoun, Tunis, Tunisia

HOMEIDA, Professor M. Department of Medicine, University of Khartoum,
P.O. Box 102, Khartoum, Sudan

LAMOTHE, Dr F. Service Radiologie, Hôpital de Niamey, B.P. 11405, Niamey,
Niger

MEUDT, Professor R. Merian Iselin Spital, Föhrenstrasse 2, CH-4054 Basel,
Switzerland

MURAKAMI, Dr H. 1012 Hira Inatsuki-machi, Kaho-gun, Fukuoka Pref., Japan

QIU, Dr Dong-chuan. Institute of Antiparasitic Diseases, Sichuan Academy of
Medical Sciences, 10 University Road, Chengdu, 610041 Sichuan, China

ROCHA, Professor D. Correia da. Hospital do Açucar, Av. Fernandes Lima,
Maceio, Alagoas, Brazil

Secretariat

HATZ, Dr C. Swiss Tropical Institute, Socinstrasse 57, Postfach, CH-4002
Basel, Switzerland

JENKINS, Mrs J. Swiss Tropical Institute, Socinstrasse 57, Postfach,
CH-4002 Basel, Switzerland

WHO Secretariat

Dr N.R. Bergquist, SCH, TDR
Dr K.E. Mott, Chief SCH, CTD
Dr R.H. Morrow, TDE, TDR

ANNEX A

Investigation of pathology due to Schistosoma mansoni

STANDARD VIEWS

Linear or sector scanners may be used to assess pathology of the liver, spleen and abdominal vessels due to S. mansoni infection.

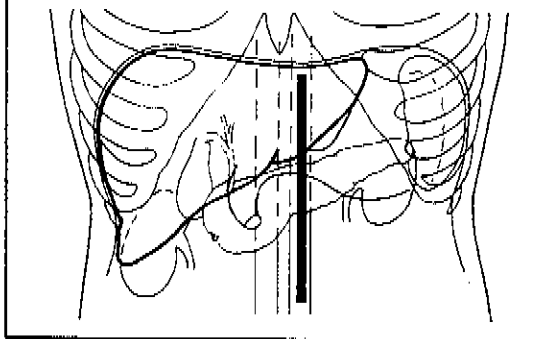
The following views should be performed routinely:

1. Longitudinal view: with the abdominal aorta as reference, the left liver lobe should be measured from the upper to the caudal margin. This view is also used to demonstrate paraumbilical and coronary vein collaterals.
2. Transverse view at the xyphoid level: this is used to assess the shape of the left liver lobe and to detect coronary and short gastric veins.
3. Subcostal transhepatic view: the probe should be placed below the right costal margin and directed cephalad. This view is used to assess the liver surface and parenchyma appearance, to detect deviation of hepatic veins, to measure periportal thickening of the peripheral branches.
4. Oblique view with the patient in semi-recumbent left-side position: the point of reference should be where the maximum diameter of the portal vein is seen. The diameter of the portal vein is measured at this position.
5. Right mid-axillary view: the probe should be placed vertically, usually with the plane through the right kidney as the point of reference. It is used to assess the size of the right liver lobe. If present, ascites can be seen with this view.
6. Left mid-axillary view: the probe should be placed vertically, usually with the plane through the left kidney as the point of reference. It is used to assess the length of the spleen. Ascites can also be seen with this view.

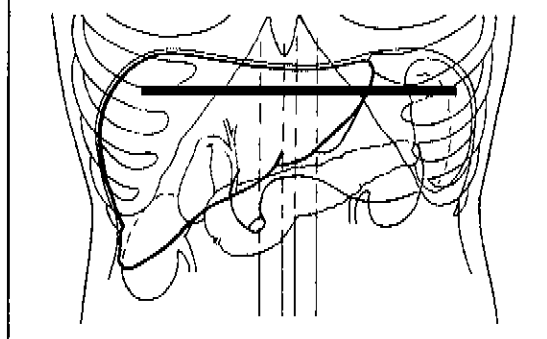
The best position for examining the gall bladder varies. It should be demonstrated in its longitudinal section to assess shape, filling state and wall thickness.

Standard scans for liver examination

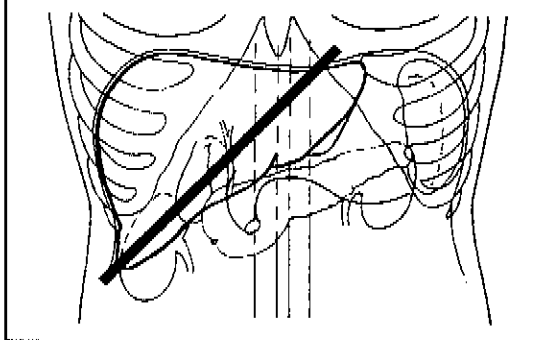
Longitudinal view directed at the abdominal aorta left of the xiphoid



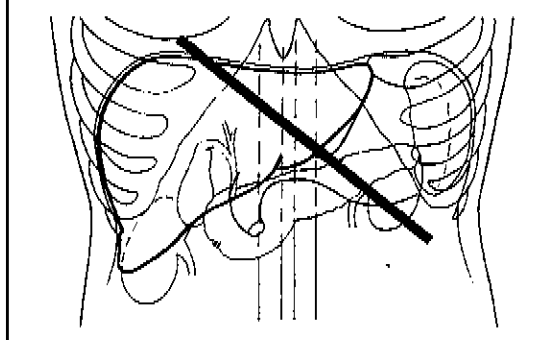
Transverse (horizontal) view at the level of the xiphoid



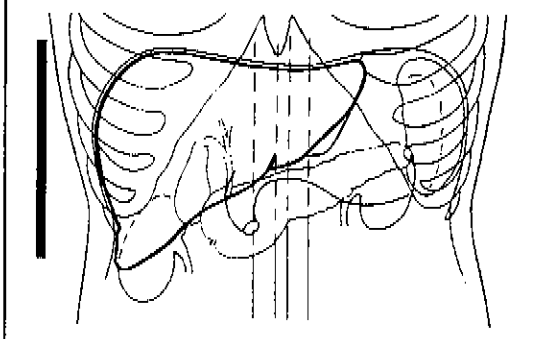
Subcostal transhepatic view directed caudally from the right costal margin



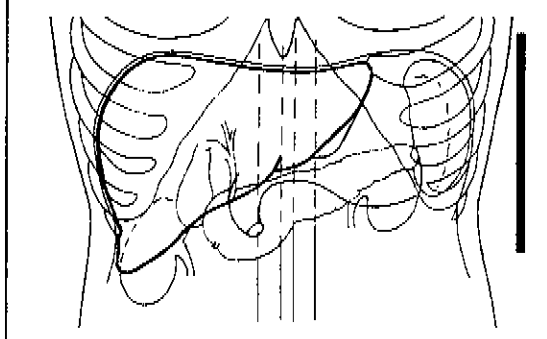
Oblique view with the patient in the semi-recumbent left-side position



Vertical right mid-axillary view through the right kidney



Vertical left mid-axillary view through the left kidney



DEFINITIONS

MODULE 1 - STANDARD INVESTIGATIONS

Liver:

Liver surface: a deviation from the normal smooth appearance of the liver surface (subcostal view, posterior margin) indicates liver pathology:

- 0 = smooth
- 1 = slight irregularity
- 2 = gross irregularity

Enlargement of the left liver lobe is usually accompanied by a "wavy" surface. A convex or straight posterior margin and a rounded caudal margin instead of the normal concavity and a sharp caudal margin are indicators of morbidity.

Size of left liver lobe (adults):

- 0 = \leq 70 mm (normal)
- 1 = $>$ 70 mm (enlarged)

The length from the upper to the caudal margin of the left liver lobe should be measured in a longitudinal section cross-sectionally with the probe positioned above the aorta as reference.

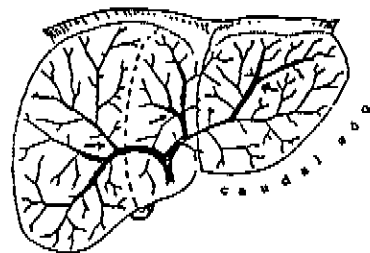
Size of right liver lobe (adults):

- 0 = $>$ 140 mm (normal)
- 1 = \leq 140mm (small, shrunken)

in the right mid-axillary view. The normal dimensions in adults and children, according to height, must be established in endemic countries.

Periportal echogenicity: thickening in this area gives rise to an increased width of echodensity around the portal tree. The average of the outer to outer measurements of three peripheral branches of the portal vein can be used for recording purposes.

- 0 = $<$ 3 mm
- 1 = 3-5 mm
- 2 = $>$ 5-7 mm
- 3 = $>$ 7 mm



Portal vein tree: measurements should be made between the first and third branching points (e.g. at position of arrows).

Portal vein:

The diameter of the lumen (inner to inner wall) should be measured mid-way between the porta hepatis and the bifurcation.

- 0 = \leq 12 mm (normal maximum internal diameter)
- 1 = $>$ 12 mm (abnormal)

Collateral veins (adult):

Collaterals include the coronary veins, paraumbilical veins, short gastric veins. Indicate whether **any** collaterals are visible:

- 0 = absent
- 1 = unable to decide
- 2 = present (specify which).

Spleen:

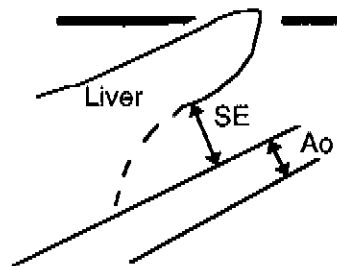
The length of the normal spleen does not exceed 120 mm in the mid-axillary line. In malarious areas, the length of the spleen may be greater in the absence of schistosomiasis.

MODULE 2 - ADDITIONAL INVESTIGATIONS

Ascites: free (visible) fluid in the abdomen.

- 0 = absent
- 1 = unable to decide
- 2 = present

Small epiploon (child): if the width of the small epiploon (SE) is more than 1.7 times the cross-sectional diameter of the aorta (Ao), it is abnormal.



Longitudinal scan for viewing
the small epiploon

Gall bladder wall: the gall bladder must be demonstrated in the fasting subject in longitudinal view.

- 0 = normal if the thickness is less than 5 mm.
- 1 = abnormal if the thickness of the entire wall is equal to or exceeds 5 mm.

The anterior wall must be measured because the posterior wall may appear thicker than 5 mm normally. The wall thickness can only be assessed when the gall bladder is adequately filled, i.e. in the fasting subject. The contracted gall bladder shows two layers, i.e. a double line.

Liver parenchyma:

Echogenic lesions (spots) in the liver parenchyma which are not clearly attached to the portal vein or its branches. They have been reported in adults only.

Peripheral portal branches:

The inner to inner wall measurement (i.e. the lumen) of the peripheral portal branches may also be measured, to provide the data for the comparison of two different methods of assessing periportal thickening.

Cairo WHO Workshop

Record-sheet for *S. mansoni* pathology-ultrasound findings

Name

Notes

Patient number

Date of examination

mm.dd.yy

Age

years

Sex

 male female

Height

cm

Weight

kg

MODULE 1 – STANDARD INVESTIGATIONS**Liver**

Periportal measurement (outer to outer wall) of 3 different peripheral branches

mm mm mm

Average measurement

mm

0 = < 3

1 = 3 – 5

2 = > 5 – 7

3 = > 7

Size of left lobe (longitudinal section)

mm

0 = ≤ 70 mm

1 = > 70 mm

Liver surface irregularity

0 = none

1 = slight

2 = gross

Shape of left lobe

Dorsal surface

0 = concave

1 = convex

Caudal edge

0 = sharp

1 = round

Size of right lobe (longitudinal section)

mm

0 = ≥ 140 mm

1 = < 140 mm

Portal vein

Diameter (inner to inner wall)

mm

0 = < 12 mm

1 = ≥ 12 mm

Collateral veins (adult)

0 = absent

1 = unable to decide

2 = present

Coronary veins

0 = not present

1 = present

Paraumbilical veins

0 = not present

1 = present

Short gastric veins

0 = not present

1 = present

Spleen

Length

mm

0 = ≤ 120 mm

1 = > 120 mm

Cairo WHO Workshop	
Record-sheet for <i>S. mansoni</i> pathology-ultrasound findings	
Name	
Notes	
Patient number	<input type="text"/> <input type="text"/> <input type="text"/> <input type="text"/> <input type="text"/> <input type="text"/> <input type="text"/> <input type="text"/>
Date of examination	mm.dd.yy <input type="text"/> <input type="text"/> . <input type="text"/> <input type="text"/> . <input type="text"/> <input type="text"/>
Age	years <input type="text"/> <input type="text"/>
Sex	<input type="checkbox"/> male <input type="checkbox"/> female
Height	cm <input type="text"/> <input type="text"/> <input type="text"/>
Weight	kg <input type="text"/> <input type="text"/> <input type="text"/>
MODULE 2 – ADDITIONAL INVESTIGATIONS	
Ascites	
0 = absent 1 = unable to decide 2 = present	<input type="checkbox"/>
Small epiploon (child)	
0 = normal 1 = abnormal	<input type="checkbox"/>
Gallbladder wall measurement	mm <input type="text"/> <input type="text"/>
0 = < 5 mm 1 = ≥ 5 mm	<input type="checkbox"/>
Parenchymal spots of the liver	
0 = none 1 = present	<input type="checkbox"/>
Periportal measurement	
Measurement of 3 different peripheral branches	
Outer to outer diameter = D	
mm <input type="text"/> <input type="text"/> mm <input type="text"/> <input type="text"/> mm <input type="text"/> <input type="text"/> average	<input type="text"/> <input type="text"/>
Portal lumen (inner to inner wall) = d	
mm <input type="text"/> <input type="text"/> mm <input type="text"/> <input type="text"/> mm <input type="text"/> <input type="text"/> average	<input type="text"/> <input type="text"/>
Ratio	
$\frac{\text{outer to outer diameter}}{\text{inner to inner diameter}} = \frac{D}{d}$	<input type="text"/> , <input type="text"/>

Proposal for Staging of S.mansoni Infections

STAGE	O	I	II	III
Periportal thickening	-	+ / + +	+ / + + + + +	+ + / + + +
Enlarged Spleen	-	-	+	+
Enlarged left lobe	-	+ / -	+ / -	+
Shrunken right lobe	-	+ / -	+	+
Portal vein diameter increased	-	-	+	+
Collaterals (adult)	-	-	+ / -	+
<u>ADDITIONAL</u>				
Ascites	-	-	-	+
Small epiploon (child)	-	-	+ / -	+
Gallbladder wall thickening	-	-	+ / -	+

Key:

- = not pathological
- + / - = may or may not be pathological at this stage
- + / + + / + + + = pathology (grading)

ANNEX B

Investigation of Pathology due to Schistosoma haematobium

STANDARD VIEWS

A sector scanner is preferable to a linear one for the assessment of the urinary bladder and the kidneys. For practical purposes it is therefore suggested that such a probe should be used.

Adequate bladder filling is essential to assess shape and wall irregularity.

1. Transverse view of the bladder: the probe should be placed above the pubic symphysis at the maximum cross-sectional diameter of the bladder with a view of the distal part of the ureters.

2. + 3. Left and right lateral views (longitudinal section): both kidneys and the proximal part of the ureters should be observed from the lateral view in the mid-axillary line. If this is not satisfactory in children a dorsal view may be used. Distal parts of the ureters should be followed as far as possible.

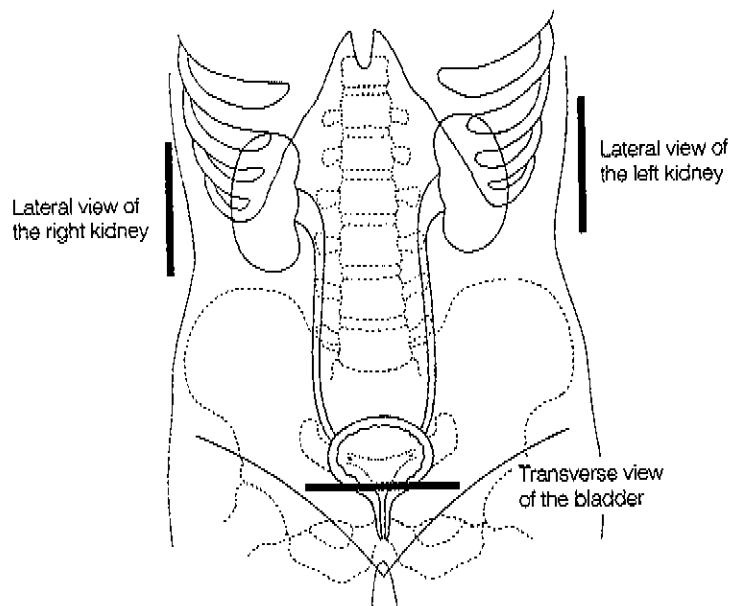
Bladder filling: if the bladder is not well filled, the normal appearance of the wall structures may be misinterpreted as pathological. Fluids must be given half an hour to one hour prior to investigation. Diuretics must not be given.

If any abnormality of the kidney and/or ureters is observed, a post-voiding examination of these organs must be done one-half to one hour later.

Spaces are provided on the form for recording the second examination if made.

To measure residual urine, both transverse and longitudinal views should be performed to measure width, depth and length.

Standard scans in urinary schistosomiasis



DEFINITIONS

MODULE 1 - STANDARD INVESTIGATIONS

Bladder:

Shape: a deviation from the normal rectangular shape of the well-filled bladder indicates pathology.

0 = normal (rectangular); 1 = rounded (distorted)

Wall thickening: the thickness of the posterior bladder wall should be measured at the posterior wall in the area of the trigone.

0 = < 5 mm; 1 = ≥ 5 mm

Irregularity of inner surface of the bladder wall:

0 = absent 1 = focal 2 = diffuse

Masses: a localized thickening of the bladder wall protruding into the lumen (>10mm) is defined as a mass.

0 = none, 1 = single, 2 = more than one.

Pseudopolyps: an outgrowth of the wall, attached by a slender base, is defined as a pseudopolyp.

0 = none, 1 = single, 2 = more than one

Size and location of masses or pseudopolyps:

The largest dimension of the largest mass or polyp (width (W), depth (D) or length (L)) should be recorded, and the location noted.

Ureters:

Dilatation of the ureter:

0 = absent, ureters are not visualised;
1 = dilated, the ureter is visualized at the proximal and/or distal third;
2 = grossly dilated, the ureter is dilated more than is required for mere visualization.

Kidney:

Stage of hydronephrosis according to the criteria proposed by Weill et al.(1983) modified in the workshop.

- 1 = fissure present
- 2 = mild dilatation
- 3 = moderate dilatation with > 2 cm parenchyma
- 4 = severe dilatation with < 2 cm parenchyma
- 5 = end-stage with absence of parenchyma.

MODULE 2 - ADDITIONAL INVESTIGATIONS (not time-consuming)

Calcification:

Although almost pathognomonic of the disease, calcification may only be clearly seen (with conical shadow) in advanced cases. It should be recorded as:

0 = not visible; 1 = visible

Fibrosis of pyelon:

Echodense structures along the borders of the pyelon occur in adults and should be recorded as:

0 = not present 1 = present

MODULE 3 - RESIDUAL URINE

1. Qualitative:

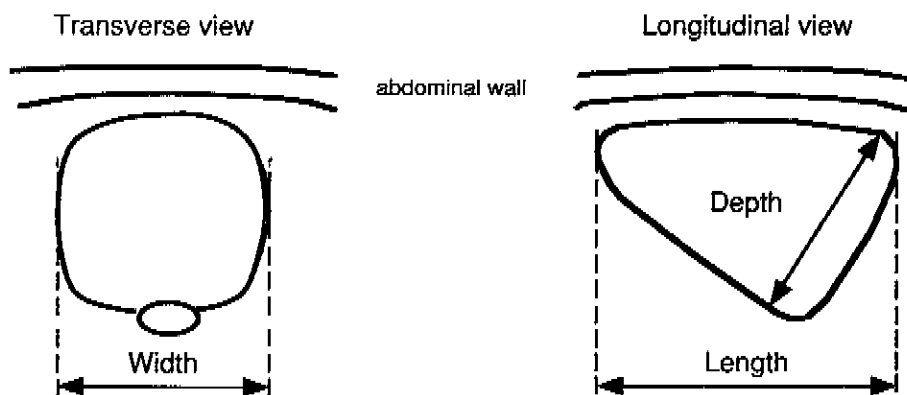
Presence (1) or absence (0) can be noted.

2. Quantitative:

Bladder volume (pre- and post-voiding) can be approximately calculated using the modified formula of McLean and Edell (Lutz and Meudt, 1982):

$$\frac{(\text{width} \times \text{depth} \times \text{length})}{2}$$

Residual urine is present when > 10% of the pre-voiding urine is found on post-voiding examination. NB: a grossly distended bladder before voiding will always have residual urine.



Calculation of the bladder volume according to Lutz and Meudt (ref. 4)

MODULE 4 - LIVER PATHOLOGY

Liver

Liver surface: a deviation from the normal smooth appearance of the liver surface (subcostal view, posterior margin) indicates liver pathology:

- 0 = smooth
- 1 = slight irregularity
- 2 = gross irregularity

Enlargement of the left liver lobe is usually accompanied by a "wavy" surface. A convex or straight posterior margin and a rounded caudal margin instead of the normal concavity and a sharp caudal margin are indicators of morbidity.

Size of left liver lobe (adults):

- 0 = \leq 70 mm (normal)
- 1 = $>$ 70 mm (enlarged)

The length from the upper to the caudal margin of the left liver lobe should be measured in a longitudinal section cross-sectionally with the probe positioned above the aorta as reference.

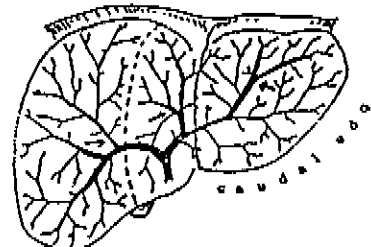
Size of right liver lobe (adults):

- 0 = $>$ 140 mm (normal)
- 1 = \leq 140mm (small, shrunken)

in the right mid-axillary view. The normal dimensions in adults and children, according to height, must be established in endemic countries.

Periportal echogenicity: thickening in this area gives rise to an increased width of echodensity around the portal tree. The average of the outer to outer measurements of three peripheral branches of the portal vein can be used for recording purposes.

- 0 = $<$ 3 mm
- 1 = 3-5 mm
- 2 = $>$ 5-7 mm
- 3 = $>$ 7 mm



Portal vein tree: measurements should be made between the first and third branching points (e.g. at position of arrows).

Portal vein:

The diameter of the lumen (inner to inner wall) should be measured mid-way between the porta hepatis and the bifurcation.

Normal maximum internal diameter: 0 = ≤ 12 mm
Pathological internal diameter: 1 = > 12 mm

Collateral veins (adult):

Collaterals include the coronary veins, paraumbilical veins, short gastric veins. Indicate whether **any** collaterals are visible

0 = absent
1 = unable to decide
2 = present (specify which).

Spleen:

The length of the normal spleen is not greater than 120 mm in the mid-axillary line. In malarious areas, the length of the spleen may be greater even in the absence of schistosomiasis.

Cairo WHO Workshop

Record-sheet for *S. haematobium* pathology-ultrasound findings

Name

Notes

Patient number

Date of examination

mm.dd.yy

. .

Age

years

Sex

male female

Height

cm

Weight

kg

MODULE 1 – STANDARD INVESTIGATIONS

Bladder

Shape

0 = normal (rectangular) 1 = round (distorted)

Thickening of wall

Distribution 0 = none 1 = focal 2 = diffuse

Thickness

mm

Grade

0 = ≤ 5 mm 1 = > 5 mm

Irregularity of inner surface

Distribution 0 = none 1 = focal 2 = diffuse

Mass

0 = none 1 = single 2 = > one

Pseudopolyp

0 = none 1 = single 2 = > one

Largest measurement

Size = L, D, W

mm

Location

Ureter

Right dilatation

1st 2nd examination

0 = - 1 = + 2 = ++

Left dilatation

1st 2nd examination

0 = - 1 = + 2 = ++

Kidney

Right: grade of pyelon dilatation

1st 2nd examination

0 = 0 1 = 1 2 = 2,3 3 = 4,5

Left: grade of pyelon dilatation

1st 2nd examination

0 = 0 1 = 1 2 = 2,3 3 = 4,5

Cairo WHO Workshop	
Record-sheet for <i>S. haematobium</i> pathology-ultrasound findings	
Name	
Notes	
Patient number	<input type="text"/> <input type="text"/> <input type="text"/> <input type="text"/> <input type="text"/> <input type="text"/> <input type="text"/> <input type="text"/>
Date of examination	mm.dd.yy <input type="text"/> <input type="text"/> . <input type="text"/> <input type="text"/> . <input type="text"/> <input type="text"/>
Age	years <input type="text"/> <input type="text"/>
Sex	<input type="checkbox"/> male <input type="checkbox"/> female
Height	cm <input type="text"/> <input type="text"/> <input type="text"/>
Weight	kg <input type="text"/> <input type="text"/> <input type="text"/>
MODULE 2 – CALCIFICATION AND FIBROSIS	
Calcification of bladder wall	
0 = not visible 1 = visible	<input type="checkbox"/>
Fibrosis of kidney pyelon (adults)	
0 = absent 1 = present	<input type="checkbox"/>

Cairo WHO Workshop	
Record-sheet for <i>S. haematobium</i> pathology-ultrasound findings	
Name	
Notes	
Patient number	<input type="text"/> <input type="text"/> <input type="text"/> <input type="text"/> <input type="text"/> <input type="text"/> <input type="text"/> <input type="text"/>
Date of examination	mm.dd.yy <input type="text"/> <input type="text"/> . <input type="text"/> <input type="text"/> . <input type="text"/> <input type="text"/>
Age	years <input type="text"/> <input type="text"/>
Sex	<input type="checkbox"/> male <input type="checkbox"/> female
Height	cm <input type="text"/> <input type="text"/> <input type="text"/>
Weight	kg <input type="text"/> <input type="text"/> <input type="text"/>
MODULE 3 – RESIDUAL URINE	
Qualitative assesement	
0 = absent	1 = present <input type="checkbox"/>
Quantitative assesement	
Measurements before voiding	
Width	mm <input type="text"/> <input type="text"/> <input type="text"/>
Length	mm <input type="text"/> <input type="text"/> <input type="text"/>
Depth	mm <input type="text"/> <input type="text"/> <input type="text"/>
Measurements after voiding	
Width	mm <input type="text"/> <input type="text"/> <input type="text"/>
Length	mm <input type="text"/> <input type="text"/> <input type="text"/>
Depth	mm <input type="text"/> <input type="text"/> <input type="text"/>
Volume before voiding	
$\frac{\text{width} \cdot \text{length} \cdot \text{depth}}{2} \cdot \frac{1}{1000}$	cm ³ <input type="text"/> <input type="text"/> <input type="text"/> <input type="text"/>
Volume after voiding	
$\frac{\text{width} \cdot \text{length} \cdot \text{depth}}{2} \cdot \frac{1}{1000}$	cm ³ <input type="text"/> <input type="text"/> <input type="text"/> <input type="text"/>
% urine after voiding	
$\frac{\text{post-voiding volume}}{\text{pre-voiding volume}} \cdot 100$	% <input type="text"/> <input type="text"/>

Cairo WHO Workshop	
Record-sheet for <i>S. haematobium</i> pathology-ultrasound findings	
Name	
Notes	
Patient number	<input type="text"/>
Date of examination	mm.dd.yy <input type="text"/>
Age	years <input type="text"/>
Sex	<input type="checkbox"/> male <input type="checkbox"/> female
Height	cm <input type="text"/>
Weight	kg <input type="text"/>
MODULE 4 – LIVER PATHOLOGY	
Liver	
Periportal measurement (outer to outer wall) of 3 different peripheral branches	
mm <input type="text"/> mm <input type="text"/> mm <input type="text"/>	
Average measurement	mm <input type="text"/>
0 = < 3 1 = 3 – 5 2 = > 5 – 7 3 = > 7	<input type="checkbox"/>
Size of left lobe (longitudinal section)	mm <input type="text"/>
0 = ≤ 70 mm 1 = > 70 mm	<input type="checkbox"/>
Liver surface irregularity	
0 = none 1 = slight 2 = gross	<input type="checkbox"/>
Shape of left lobe	
Dorsal surface 0 = concave 1 = convex	<input type="checkbox"/>
Caudal edge 0 = sharp 1 = round	<input type="checkbox"/>
Size of right lobe (longitudinal section)	mm <input type="text"/>
0 = ≥ 140 mm 1 = < 140 mm	<input type="checkbox"/>
Portal vein	
Diameter (inner to inner wall)	mm <input type="text"/>
0 = < 12 mm 1 = ≥ 12 mm	<input type="checkbox"/>
Collateral veins (adult)	
0 = absent 1 = unable to decide 2 = present	<input type="checkbox"/>
Coronary veins 0 = not present 1 = present	<input type="checkbox"/>
Paraumbilical veins 0 = not present 1 = present	<input type="checkbox"/>
Short gastric veins 0 = not present 1 = present	<input type="checkbox"/>
Spleen	
Length	mm <input type="text"/>
0 = ≤ 120 mm 1 = > 120 mm	<input type="checkbox"/>

ANNEX C

Investigation of Pathology due to Schistosoma japonicum

STANDARD VIEWS

Linear or sector scanners may be used to assess pathology of the liver, spleen and abdominal vessels due to S. japonicum infection.

The following views should be performed routinely:

1. Longitudinal view: with the abdominal aorta as reference, the left liver lobe should be measured from the upper to the caudal margin. This view is also used to demonstrate paraumbilical and coronary vein collaterals.

2. Transverse view at the xyphoid level: this is used to assess the shape of the left liver lobe and to detect coronary and short gastric veins.

3. Subcostal transhepatic view: the probe should be placed below the right costal margin and directed cephalad. This view is used to assess the liver surface and parenchyma appearance, to detect deviation of hepatic veins, to measure periportal thickening of the peripheral branches.

4. Oblique view with the patient in semi-recumbent left-side position: the point of reference should be where the maximum diameter of the portal vein is seen. The diameter of the portal vein is measured at this position.

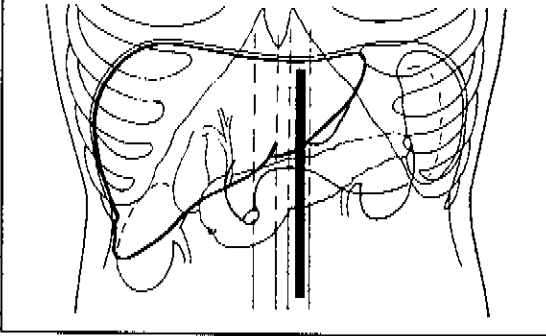
5. Right mid-axillary view: the probe should be placed vertically, usually with the plane through the right kidney as the point of reference. It is used to assess the size of the right liver lobe. If present, ascites can be seen with this view.

6. Left mid-axillary view: the probe should be placed vertically, usually with the plane through the left kidney as the point of reference. It is used to assess the length of the spleen. Ascites can also be seen with this view.

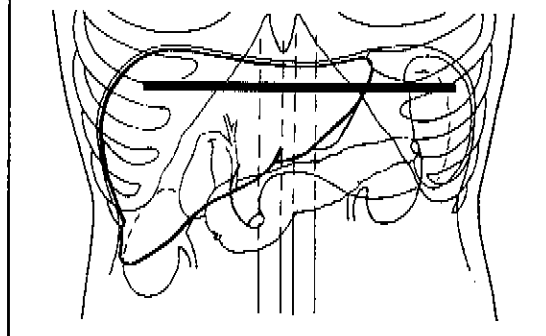
The best position for examining the gall bladder varies. It should be demonstrated in its longitudinal section to assess shape, filling state and wall thickness.

Standard scans for liver examination

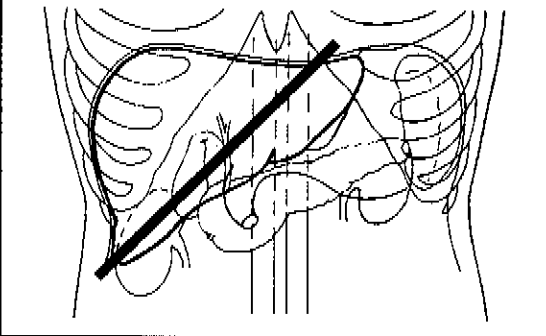
Longitudinal view directed at the abdominal aorta left of the xiphoid



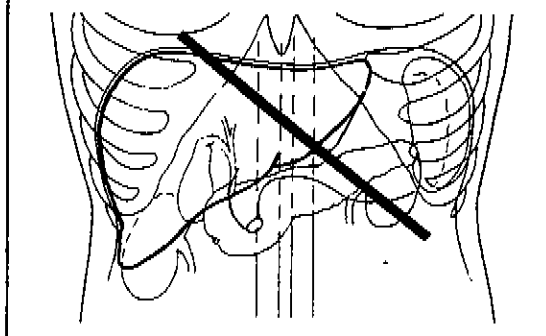
Transverse (horizontal) view at the level of the xiphoid



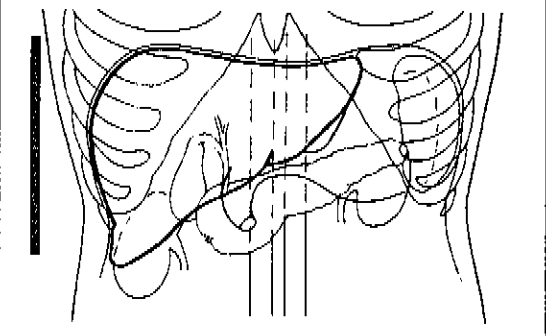
Subcostal transhepatic view directed caudally from the right costal margin



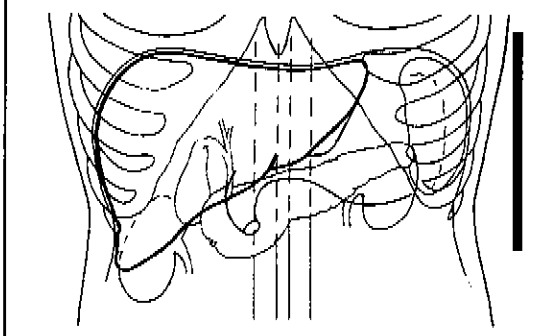
Oblique view with the patient in the semi-recumbent left-side position



Vertical right mid-axillary view through the right kidney



Vertical left mid-axillary view through the left kidney



Definitions

MODULE 1 - STANDARD INVESTIGATIONS

Liver:

Liver parenchyma: the changes of the liver parenchyma described below can be readily seen in the right lobe and appear to be specific for *S. japonicum* infection. These lesions correspond most probably to fibrous changes of the liver architecture, but they have not been fully explained anatomically.

- | | |
|-----------|---|
| Grade I | Focal echodense areas, scattered within the liver parenchyma with absence of definite borders. |
| Grade II | Stronger light bands forming a "fish-scale" pattern.
A few focal echodense areas > 20 mm in diameter. |
| Grade III | Echodense bands forming a contiguous network; multiple focal echodense areas > 20 mm in diameter. Masses with central fibrosis. |

Liver surface: a deviation from the normal smooth appearance of the liver surface (subcostal view, posterior margin) indicates liver pathology:

- 0 = smooth
- 1 = slight irregularity
- 2 = gross irregularity

Enlargement of the left liver lobe is usually accompanied by a "wavy" surface. A convex or straight posterior margin and a rounded caudal margin instead of the normal concavity and a sharp caudal margin are indicators of morbidity.

Size of left liver lobe (adults):

- 0 = \leq 70 mm (normal)
- 1 = $>$ 70 mm (enlarged)

The length from the upper to the caudal margin of the left liver lobe should be measured in a longitudinal section cross-sectionally with the probe positioned above the aorta as reference.

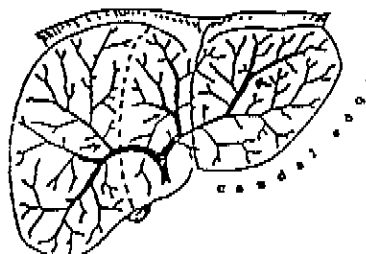
Size of right liver lobe (adults):

- 0 = $>$ 140 mm (normal)
- 1 = \leq 140mm (small, shrunken)

in the right mid-axillary view. The normal dimensions in adults and children, according to height, must be established in endemic countries.

Periportal echogenicity: thickening in this area gives rise to an increased width of echodensity around the portal tree. The average of the outer to outer measurements of three peripheral branches of the portal vein can be used for recording purposes.

- 0 = < 3 mm
- 1 = 3-5 mm
- 2 = >5-7 mm
- 3 = >7 mm



Portal vein tree: measurements should be made between the first and third branching points (e.g. at position of arrows).

Portal vein:

The diameter of the lumen (inner to inner wall) should be measured mid-way between the porta hepatis and the bifurcation.

- 0 = \leq 12 mm (normal maximum internal diameter)
- 1 = > 12 mm (abnormal)

Spleen:

The length of the normal spleen does not exceed 100 mm in the mid-axillary view. In malarious areas, the length of the spleen may be greater in the absence of schistosomiasis. (Note: The value of 100 mm rather than 120 mm has been recommended for use in Asia.)

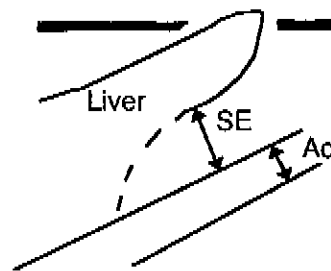
MODULE 2 - ADDITIONAL INVESTIGATIONS

Ascites: free (visible) fluid in the abdomen.

- 0 = absent
- 1 = unable to decide
- 2 = present

Collaterals (adult) : absent (0), unable to decide (1), present (2). Collaterals include the coronary veins, paraumbilical veins, short gastric veins. Indicate visible collaterals. If visible, specify which.

Small epiploon (child): if the width of the small epiploon (SE) is more than 1.7 times the cross-sectional diameter of the aorta (Ao), it is abnormal.



Longitudinal scan for viewing
the small epiploon

Gall bladder wall: the gall bladder must be demonstrated in the fasting subject in longitudinal view.

- 0 = normal if the thickness is less than 5 mm.
- 1 = abnormal if the thickness of the entire wall is equal to or exceeds 5 mm.

The anterior wall must be measured because the posterior wall may appear thicker than 5 mm normally. The wall thickness can only be assessed when the gall bladder is adequately filled, i.e. in the fasting subject. The contracted gall bladder shows two layers, i.e. a double line.

Hepatic vein deviation: in chronic cases the hepatic veins may be displaced from their normal structure as a result of the pathological changes of the liver parenchyma.

Peripheral portal branches: the inner to inner diameter (i.e. the lumen) of the peripheral portal branches may also be measured, to provide the data for the comparison of two different methods of assessing periportal thickening.

Cairo WHO Workshop	
Record-sheet for <i>S. japonicum</i> pathology-ultrasound findings	
Name	
Notes	
Patient number	<input type="text"/>
Date of examination	mm.dd.yy <input type="text"/>
Age	years <input type="text"/>
Sex	<input type="checkbox"/> male <input type="checkbox"/> female
Height	cm <input type="text"/>
Weight	kg <input type="text"/>
MODULE 1 – STANDARD INVESTIGATIONS	
Liver	
Appearance of parenchyma	
0 = normal 1 = Grade I 2 = Grade II 3 = Grade III	<input type="checkbox"/>
Size of left lobe (longitudinal section)	mm <input type="text"/>
0 = ≤ 70 mm 1 = > 70 mm	<input type="checkbox"/>
Liver surface irregularity	
0 = none 1 = slight 2 = gross	<input type="checkbox"/>
Shape of left lobe	
Dorsal surface 0 = concave 1 = convex	<input type="checkbox"/>
Caudal edge 0 = sharp 1 = round	<input type="checkbox"/>
Size of right lobe (longitudinal section)	mm <input type="text"/>
0 = ≥ 140 mm 1 = < 140 mm	<input type="checkbox"/>
Periportal measurement (outer to outer wall) of 3 different peripheral branches	
mm <input type="text"/> mm <input type="text"/> mm <input type="text"/>	
Average measurement	mm <input type="text"/>
0 = < 3 1 = 3 – 5 2 = > 5 – 7 3 = > 7	<input type="checkbox"/>
Portal vein	
Diameter (inner to inner wall)	mm <input type="text"/>
0 = < 12 mm 1 = ≥ 12 mm	<input type="checkbox"/>
Spleen	
Length	mm <input type="text"/>
0 = ≤ 100 mm 1 = > 100 mm	<input type="checkbox"/>

Cairo WHO Workshop	
Record-sheet for <i>S. japonicum</i> pathology-ultrasound findings	
Name	
Notes	
Patient number	<input type="text"/> <input type="text"/> <input type="text"/> <input type="text"/> <input type="text"/> <input type="text"/> <input type="text"/> <input type="text"/>
Date of examination	mm.dd.yy <input type="text"/> <input type="text"/> . <input type="text"/> <input type="text"/> . <input type="text"/> <input type="text"/>
Age	years <input type="text"/> <input type="text"/>
Sex	<input type="checkbox"/> male <input type="checkbox"/> female
Height	cm <input type="text"/> <input type="text"/>
Weight	kg <input type="text"/> <input type="text"/>
MODULE 2 – ADDITIONAL INVESTIGATIONS	
Ascites	
0 = absent 1 = unable to decide 2 = present	<input type="checkbox"/>
Small epiploon (child)	
0 = normal 1 = abnormal	<input type="checkbox"/>
Gallbladder wall measurement	mm <input type="text"/> <input type="text"/>
0 = < 5 mm 1 = ≥ 5 mm	<input type="checkbox"/>
Hepatic veins: deviation	
0 = none 1 = present	<input type="checkbox"/>
Periportal measurement	
Measurement of 3 different peripheral branches	
Outer to outer diameter = D	
mm <input type="text"/> <input type="text"/> mm <input type="text"/> <input type="text"/> mm <input type="text"/> <input type="text"/> average	<input type="text"/> <input type="text"/>
Portal lumen (inner to inner wall) = d	
mm <input type="text"/> <input type="text"/> mm <input type="text"/> <input type="text"/> mm <input type="text"/> <input type="text"/> average	<input type="text"/> <input type="text"/>
Ratio	
$\frac{\text{outer to outer diameter}}{\text{inner to inner diameter}} = \frac{D}{d}$	<input type="text"/> , <input type="text"/>
Collateral veins (adult)	
0 = absent 1 = unable to decide 2 = present	<input type="checkbox"/>
Coronary veins 0 = not present 1 = present	<input type="checkbox"/>
Paraumbilical veins 0 = not present 1 = present	<input type="checkbox"/>
Short gastric veins 0 = not present 1 = present	<input type="checkbox"/>

Proposal for Staging of S.japonicum Infections

STAGE	O	I	II	III
Parenchymal classification	-	+	++	+++
Periportal thickening	-	+ / ++	+ / +++	++ / +++
Enlarged Spleen	-	-	+	+
Enlarged left lobe	-	+ / -	+ / -	+ / -
Shrunken right lobe	-	+ / -	+	+
Portal vein diameter increased	-	-	+	+
<u>ADDITIONAL</u>				
Ascites	-	-	-	+ / -
Collaterals (adult)	-	-	+ / -	+
Small epiploon (child)	-	-	+ / -	+
Gallbladder wall thickening	-	-	+ / -	+ / -
Deviation of hepatic vein	-	-	+ / -	+

Key:

- = not pathological
- + / - = may or may not be pathological at this stage
- + / ++ / +++ = pathology (grading)

* * *