

# **ULTRASOUND IN SCHISTOSOMIASIS**

## **A Practical Guide to the Standardized Use of Ultrasonography for the Assessment of Schistosomiasis-related Morbidity**

Second International Workshop  
October 22 - 26, 1996, Niamey, Niger



UNDP/World Bank/WHO  
Special Programme for Research & Training in Tropical Diseases  
(TDR)

This document is not a formal publication of the World Health Organization (WHO), and all rights are reserved by the Organization. The document may, however, be freely reviewed, abstracted, reproduced or translated, in part or in whole, but not for sale or for use in conjunction with commercial purposes.

The views expressed in documents by named authors, are solely the responsibility of those authors.

© World Health Organization 2000

# ULTRASOUND IN SCHISTOSOMIASIS

## A Practical Guide to the Standardized Use of Ultrasonography for the Assessment of Schistosomiasis-related Morbidity

Second International Workshop  
October 22 - 26, 1996, Niamey, Niger

This report includes the views of an expert group, Satellite Symposium on Ultrasound  
Methodology in *Schistosoma mansoni* infection which met  
October 19-24, 1997, Belo Horizonte, Brazil

Editors: J. Richter, C. Hatz, G. Campagne, N. R. Bergquist, J. M. Jenkins

### Addresses for correspondence

Dr J. Richter  
Faculty of Medicine,  
Clinics for Gastroenterology, Hepatology and Infectious Diseases,  
Heinrich Heine Universität, Moorenstrasse 5,  
D-40225 Düsseldorf., FR Germany  
e-mail [Joachim.Richter@med.uni-duesseldorf.de](mailto:Joachim.Richter@med.uni-duesseldorf.de)

Dr G. Campagne,  
CERMES,  
B. P. 10887  
Niamey,  
Niger  
e-mail [gerard.campagne@wanadoo.fr](mailto:gerard.campagne@wanadoo.fr)

Dr C. Hatz, Mrs J.M. Jenkins,  
Swiss Tropical Institute,  
Socinstrasse 57,  
4002 Basel,  
Switzerland  
e-mail [christoph.hatz@unibas.ch](mailto:christoph.hatz@unibas.ch)  
[Jennifer.Jenkins@unibas.ch](mailto:Jennifer.Jenkins@unibas.ch)

Dr N. R. Bergquist,  
WHO/TDR  
1211 Geneva 27  
Switzerland  
e-mail [bergquistr@who.int](mailto:bergquistr@who.int)



# Table of Contents

<b>INTRODUCTION .....</b>	<b>1</b>
<b>PART 1: REPORT OF THE WORKSHOP .....</b>	<b>2</b>
<b>1.1 AIMS .....</b>	<b>2</b>
<b>1.2 MORBIDITY DUE TO SCHISTOSOMIASIS, AND ITS EVOLUTION AFTER CHEMOTHERAPY .....</b>	<b>2</b>
<i>Morbidity due to Schistosoma haematobium infection .....</i>	<i>2</i>
<i>Morbidity due to Schistosoma mansoni infection.....</i>	<i>3</i>
<i>Morbidity due to Schistosoma species occurring in Asia.....</i>	<i>4</i>
<b>1.3 REVISION OF STANDARDIZED PROCEDURES AND PREPARATION OF NEW PROTOCOLS .....</b>	<b>4</b>
<i>Criteria for choice of methods .....</i>	<i>4</i>
<i>Grading and scoring of lesions .....</i>	<i>5</i>
<i>Quality control and the reduction of variance .....</i>	<i>6</i>
<i>Standard protocols for ultrasound examination: S. haematobium .....</i>	<i>6</i>
<i>Standard protocols for ultrasound examination: S. mansoni.....</i>	<i>7</i>
<b>1.4 RECOMMENDATIONS FOR CONTROL PROGRAMMES .....</b>	<b>8</b>
<i>General aspects.....</i>	<i>8</i>
<i>Recommendations for control programmes: S. haematobium .....</i>	<i>9</i>
<i>Recommendations for control programmes: S. mansoni .....</i>	<i>9</i>
<b>1.5 PRIORITIES FOR FUTURE RESEARCH .....</b>	<b>9</b>
<i>General .....</i>	<i>9</i>
<i>Research priorities for S. haematobium.....</i>	<i>10</i>
<i>Research priorities for S. mansoni.....</i>	<i>10</i>
<i>Research priorities for S. japonicum and other Asian species.....</i>	<i>10</i>
<b>1.6 CONCLUSIONS.....</b>	<b>11</b>
<b>PARTICIPANTS IN THE NIAMEY WORKSHOP .....</b>	<b>13</b>
<b>SATELLITE SYMPOSIUM: ULTRASONOGRAPHY IN METHODOLOGY IN S. MANSONI INFECTION .....</b>	<b>15</b>
<b>BIBLIOGRAPHY .....</b>	<b>17</b>

<b>PART 2: INVESTIGATION OF PATHOLOGY DUE TO <i>S. HAEMATOBIIUM</i></b> .....	<b>19</b>
<b>2.1 METHODOLOGY</b> .....	<b>19</b>
<i>Equipment</i> .....	19
<i>Preparation: bladder filling</i> .....	19
<i>Recording of pregnancy</i> .....	19
<i>Standard views</i> .....	19
<b>2.2 INTERMEDIATE AND GLOBAL SCORES</b> .....	<b>20</b>
<b>2.3 MODULE 1: STANDARD INVESTIGATIONS; DEFINITIONS AND SCORES</b> .....	<b>20</b>
2.3.1 <i>Urinary bladder</i> .....	20
2.3.2 <i>Ureters</i> .....	22
2.3.3 <i>Kidneys</i> .....	22
<b>2.4 MODULE 2: ADDITIONAL INVESTIGATIONS; DEFINITIONS AND SCORES</b> .....	<b>23</b>
2.4.1 <i>Urinary Bladder</i> .....	23
2.4.2 <i>Kidney: fibrosis of the pyelon</i> .....	24
2.4.3 <i>Liver: pathological changes</i> .....	24
<b>2.5 FORMS FOR RECORDING RESULTS</b> .....	<b>25</b>
<b>PART 3: INVESTIGATION OF PATHOLOGY DUE TO <i>S. MANSONI</i></b> .....	<b>29</b>
<b>3.1 METHODOLOGY</b> .....	<b>29</b>
<i>Equipment</i> .....	29
<i>Preparation</i> .....	29
<i>Standard views</i> .....	30
<b>3.2 IMAGE PATTERN OF LIVER PARENCHYMA → IP SCORE</b> .....	<b>32</b>
<b>3.3 PERIportal THICKENING (PT) SCORE AND LIVER SIZE</b> .....	<b>34</b>
3.3a <i>Periportal Thickening (PT) score</i> .....	34
3.3b <i>Liver size and non-specific liver abnormalities</i> .....	35
<b>3.4 PORTAL HYPERTENSION SCORES</b> .....	<b>36</b>
<b>3.5 SEQUENCE OF EXAMINATIONS AND SCORING PROCEDURE</b> .....	<b>37</b>
<b>3.6 INTERPRETATION OF THE FINAL SCORE</b> .....	<b>38</b>
<b>3.7 ADDITIONAL INVESTIGATIONS</b> .....	<b>39</b>
<b>3.8 FORMS FOR RECORDING RESULTS</b> .....	<b>41</b>
<b>ANNEX A: IMAGE PATTERNS IN THE LIVER PARENCHYMA, OBSERVED BY         ULTRASONOGRAPHY</b> .....	<b>45</b>
<b>ANNEX B: MEASUREMENT OF THE DIAMETER OF A SECOND ORDER PORTAL BRANCH</b> .....	<b>47</b>
<b>ANNEX C: ORGANOMETRY</b> .....	<b>48</b>

## INTRODUCTION

The aim of schistosomiasis control programmes is to reduce morbidity. However, most of the widely-used methods for assessing the success of interventions use parameters like egg-counts, which measure the level of infection but do not provide direct evidence about pathological changes. The planning of interventions so that they are effective in reducing damage to internal organs requires knowledge of what changes occur, how fast and how far they can be reversed by treatment, and how soon they appear again after reinfection. Ultrasonography is an excellent way of obtaining such information, not only in the hospital setting but in surveys at the community level, and it has been used for this purpose in many endemic areas. However, if these data are to be used to build up an overall picture on a world-wide scale that can be used as a basis for planning control programmes, it is necessary to have results that can be reliably compared. This is not always possible at present, because different investigators have selected different examination techniques and measurements out of the wide range of possibilities available.

One solution to the problem of obtaining comparable data from different ultrasound studies is the use of standardized protocols for examination and reporting. The first step towards developing such protocols was taken in Cairo in 1990. At a workshop sponsored by WHO/TDR and the Swiss Tropical Institute, scientists, clinicians and control officers discussed their experience of using ultrasound in schistosomiasis, especially in surveys and field studies. They identified areas where more research was needed, and proposed a set of standardized examinations and reporting procedures. The results were published in detail in a review (Cairo Working Group 1992), and a White Paper Report with detailed practical instructions (WHO 1991).

As the participants in the workshop hoped, the publication of the White Paper Report led to a number of studies using the standard protocols. In 1996, a second workshop to discuss the accumulated experience was held in Niamey, Niger, in collaboration with the Centre for Research on Meningitis and Schistosomiasis (CERMES/OCCGE). A Brazilian expert group also met to discuss ultrasound methodology for *S. mansoni* infection at a Satellite Symposium of the 6th International Symposium on Schistosomiasis, Belo Horizonte, Brazil, in October 1997. The Niamey meeting concentrated on *S. haematobium* and *S. mansoni* infections, as new data were available for these species. Another workshop will review the protocols for *S. japonicum* and other species prevalent in Asia.

Part 1 of the present White Paper Report summarises the discussions at the Niamey Workshop and in Belo Horizonte, and Parts 2 and 3 present a series of protocols with detailed instructions for standardized procedures for ultrasonographic examination, forms for recording results, and information about calculating scores and indices of severity.

The procedures given are for *S. mansoni* and *S. haematobium*. Protocols for species prevalent in Asia are not included as these have not yet been revised. However, most of the investigations suggested for *S. mansoni* are equally relevant for intestinal schistosomiasis due to other species. Therefore it is recommended that until new protocols are published, studies should use the protocols given here for *S. mansoni*. Information on pathology specific to *S. japonicum* can be added using the 1991 protocols.

## **PART 1: REPORT OF THE WORKSHOP**

### **1.1 AIMS**

The aims of the Niamey workshop were :

1. to review the status of knowledge about morbidity resulting from schistosomal infection in different endemic areas, especially the pathological changes observed using ultrasound, and the way these change over time and in response to chemotherapy;
2. to discuss and revise the standard protocols for ultrasonography presented in the White Paper Report published in 1991, in the light of subsequent experience;
3. to formulate recommendations for treatment and retreatment strategies to be used in control programmes;
4. to establish priorities for future research.

### **1.2 MORBIDITY DUE TO SCHISTOSOMIASIS, AND ITS EVOLUTION AFTER CHEMOTHERAPY**

#### **Morbidity due to *Schistosoma haematobium* infection**

The prevalence and severity of pathological changes detected by ultrasound correlate with the intensity of infection, as measured by the frequency and quantity of eggs excreted in the urine, and with indirect indicators like haematuria. In most endemic areas, a peak of morbidity is observed in children aged 7 - 14 years. Lesions observed using ultrasound are hydronephrosis, dilatation of the ureter and the formation of intravesical masses. Calcification of the bladder wall is a pathognomonic sign. Generally, hydronephrosis is the sign that has the most unfavourable prognosis.

Schistosomal infection, especially with *S. haematobium*, can cause lesions in both male and female genital tracts. There are reports that genital schistosomiasis affects reproductive health, and it has been suggested that the lesions present could offer an entry-point for other infections. Genital schistosomiasis has been relatively little studied, but some investigations of changes in the genital organs using ultrasound have been published (e.g. Abul-Khair et al. 1980, Richter et al. 1995, Vilana et al. 1997). It has also been suggested that liver abnormalities may also occur as a result of *S. haematobium* infection, but this is still a matter of debate (Nafeh et al. 1992, Nooman et al. 1995, Eltoum et al. 1993).

Bladder cancer may be related to urinary schistosomiasis in some endemic areas. Differential diagnosis is rarely a problem, since changes due to schistosomiasis are generally seen in childhood and adolescence, and regress after antiparasitic treatment, whereas cancer occurs in adults (Mostafa et al. 1995). If there is doubt, cystoscopy should be carried out.

#### *Evolution of pathological changes*

Longitudinal studies over periods of between 18 and 24 months in communities in different endemic areas have confirmed that praziquantel treatment effectively reduces the prevalence of pathological changes in the urinary tract. Both the prevalence and the severity of pathology were reduced within 6 months after treatment. Pathological changes in the upper and lower urinary tract usually regressed in parallel, though in some studies dilatation of the upper urinary tract was found to disappear later. Urinary tract pathology resolves at all ages, but some studies found that treatment was more efficacious in children.

The period before lesions reappear after treatment depends on the endemic area, the level of exposure and the intensity of reinfection. Reappearance is more rapid in children under 10 years old. In an area with high transmission and a high rate of reinfection severe lesions were already seen again 24 months after treatment. (Hatz et al 1998).

### **Morbidity due to *Schistosoma mansoni* infection**

In highly endemic areas, chronic *S. mansoni* infection affects a significant proportion of the population. The disease mostly involves the colon, liver and spleen, with reactive splenic hyperplasia and hepatic fibrosis in the first stage, and later portal hypertension. Sudden life-threatening haemorrhage may occur due to the rupture of gastro-oesophageal varices, the most common complication of periportal fibrosis.

Comparative studies indicate that the pattern of pathological change due to *S. mansoni* shows some geographical variation. In North Africa and East Africa involvement of the liver seems to be considerably more severe than in West Africa.

Ultrasonography can be used to detect periportal fibrosis and portal hypertension (dilatation of the portal and splenic veins and porto-systemic collaterals). It has proved to be more reliable than clinical methods for the diagnosis of hepatosplenic pathology. Periportal fibrosis, which is the essential lesion, is generally seen after years of infection, but it has been found in children.

Intestinal wall thickening can also be detected by ultrasonography (Dittrich et al 1994) and/or hydro-ultrasonography, but it is not specific for schistosomiasis. Polyps can be detected by hydro-ultrasonography, which may offer an alternative to colonoscopy even outside a hospital. However, it is time-consuming and in some regions it is culturally not well accepted, so it is not suitable for large-scale surveys.

In patients with hepatosplenic schistosomiasis, portal vein thrombosis is sometimes observed, especially after surgery. Hyperechogenic foci may be detected in the spleen (Cerri et al 1984). The assessment of schistosomiasis-related pulmonary hypertension requires echocardiographic devices that are at present restricted to hospital use (Emanuel et al 1987). Ectopic schistosomiasis may sometimes be detectable by ultrasonography (Bahakim et al 1986).

Acute schistosomiasis is seldom observed in hyperendemic areas, but may occur sporadically in travellers or migrants from non-endemic to endemic areas. It is characterised by liver and spleen enlargement, but characteristic changes in the texture of the liver parenchyma are not observed. Hilar lymph nodes may be enlarged and show particular changes in morphology (Lambertucci et al 1994).

### *Assessment using methods other than ultrasound*

Some signs of *S. mansoni* infection may be reported by patients, such as abdominal pain, bloody stools or haematemesis. However, these signs are not specific. Clinical examination should include signs of anaemia, liver enlargement and changes in liver and spleen consistency. Since the method for detecting liver enlargement is not standardized, the procedure used must be clearly reported. In adults, the left liver lobe is generally considered to be enlarged when palpation and/ or percussion detect it more than 3 cm below the xiphoid process. The right liver lobe is usually assessed in the right midclavicular line; in adults it is considered enlarged if it extends more than 2 cm below the costal margin, or 12 cm as assessed by combined percussion and palpation. In children, liver palpability may vary from 0-2.5 cm to 0-4 cm below the costal margin, depending on age. For enlargement of the spleen, Hackett's classification can be used. Clinical examination should also look for subcutaneous collaterals and ascites.

Rectal biopsies taken during rectoscopy can confirm intestinal involvement. Schistosome eggs may be detected in microscopic examination of fresh samples. Histological examination can show whether the eggs are surrounded by an inflammatory granuloma. More invasive examinations such as colonoscopy or a barium enema can only be carried out in a hospital.

#### *Evolution of pathological changes*

Treatment of intestinal schistosomiasis generally leads to a reduction of infection levels and improvement in clinical findings such as bloody diarrhoea, intestinal polyposis, hepatosplenomegaly, and periportal fibrosis. Reduction of periportal fibrosis should prevent the appearance of portal hypertension, and may even result in a reduction of portal pressure. (Homeida et al. 1996).

Liver fibrosis as revealed by ultrasonography generally regresses, though in certain subjects the pathological changes seem to be insensitive to treatment. The time required for regression depends on the severity of the initial involvement, the intensity of reinfection, the age of the subject and possibly on genetic factors. Improvement in pathology is always slow, and can only be seen after several months or even years. Regression is more marked in children, and in patients who initially showed only a slight fibrosis

The regression of liver and spleen enlargement after mass treatment may be hard to assess owing to methodological problems with the measurement of organs in clinical examinations, or be masked by other diseases - for example malaria, which can also cause splenomegaly. At the community level, a reduction in the number of deaths due to haematemesis may be difficult to evaluate because records of deaths and their causes is incomplete.

#### **Morbidity due to *Schistosoma* species occurring in Asia**

Morbidity due to *S. japonicum* was not discussed in detail in Niamey. A workshop on *Schistosoma* species occurring in Asia is planned when data from new ultrasonographic studies are available. Most ultrasonographic features appear to be similar to those observed in *S. mansoni* infection. Image patterns have been described (Ohmae et al. 1992). A particular network pattern is observed, which has been likened to fish-scales or a tortoise-shell, but its clinical significance is still unclear (Yi et al 1992, Ohmae et al 1992, Hatz et al 1992).

Experience with *S. mekongi* is even more limited. A study in Cambodia carried out since the workshop showed pathological changes resembling those seen in *S. mansoni* infection rather than in schistosomiasis due to *S. japonicum* (Hatz et al. 1996). No data are available on *S. malayensis*.

### **1.3 REVISION OF STANDARDIZED PROCEDURES AND PREPARATION OF NEW PROTOCOLS**

#### **Criteria for choice of methods**

The criteria for standardized procedures formulated in Cairo in 1990 were also the basis for the discussions in Niamey.

1. The procedures should be suitable for use in surveys at the community level and in field studies, and should therefore be designed to obtain essential information in a short examination (5 - 10 minutes per person). The procedures are not intended for the diagnosis of individual patients in a hospital setting.
2. Abnormalities should be selected that:
  - specifically indicate schistosomiasis

- indicate that the disease is likely to develop into a severe form
  - are typical of chronic infection.
  - are likely to change in response to treatment.
3. The investigations chosen should provide simple and unambiguous images that can be identified reliably and measured accurately, and do not produce too many false-positive results.
  4. Data collected should as far as possible be presented in a quantitative form so that changes after treatment can be monitored.

Experience of using the standardized protocols for investigation of lesions due to *S. haematobium* and *S. mansoni* was used as a basis for modifying the protocols where necessary. The discussions and recommendations for the two species are reported in detail below.

The technical recommendations, such as the preparation of subjects and the standard positions of probes, were re-endorsed with small modifications. The standard positions are particularly important for the measurement of organ size (liver, spleen). The grading and scoring of lesions was revised, and a weighted scoring system proposed. The problem of variance was raised, and recommendations made on quality control.

### **Grading and scoring of lesions**

The grading of pathology was revised to improve reliability and reduce the influence of biometric factors. A scoring system was established which gives due weight to abnormalities which reflect an unfavourable prognosis. Methods of calculating an overall index of severity were added.

The question of the cut-off points to distinguish between normal, suspicious and abnormal findings was discussed. The range of borderline pathology is large, which is not surprising, since schistosomiasis is a progressive disease. Cut-off points at which borderline findings are considered abnormal were proposed. However, different cut-off points might be appropriate for particular studies, according to the information needed. For example, in a situation where it is important to identify all cases, it may be necessary to set the cut-off point to include all doubtful cases, accepting that there will be a lot of false positives.

Definition of a universally acceptable cut-off between normal and abnormal findings proved to be more difficult for liver pathology than for the urinary tract. A “gold standard” reference for classifying ultrasound observations by comparing them with direct observations of pathology *in vivo* is not available. It would be difficult to obtain, since at early stages of infection liver biopsy might miss the fibrotic foci, and it would be ethically unjustified to perform large numbers of biopsies in people with only mild infections. Moreover, periportal fibrosis evolves progressively from the confluence of fibrotic granulomata which have microscopic dimensions to fibrotic areas which might involve great parts of the liver. This means that the choice of a cut-off even on pathological grounds would be arbitrary.

It is important not to limit cases recorded as positive for periportal fibrosis to those where ultrasound examination reveals pathological changes unequivocally. The detection of mild pathology is not important in clinical practice, since patients with “borderline” abnormalities have never been observed to suffer complications such as variceal bleeding. However, in epidemiological studies and treatment programmes it is important to detect cases of incipient periportal fibrosis, since in these patients treatment can prevent the development of severe disease, and early lesions are most likely to regress as a result of treatment. It is also important to be able to detect mild pathology in studies investigating the resolution of pathology after treatment. Therefore the concept of borderline pathology is taken into account in the protocols and scoring system.

## Quality control and the reduction of variance

However carefully the methods are standardized, assessment of the images provided by ultrasonography is always to some extent subjective, and studies of inter- and intra-observer variation have confirmed this (Doehring-Schwerdtfeger et al 1992).

An examiner with adequate training can distinguish those cases with normal findings from those with clear-cut pathological changes, so that individuals in danger of developing severe disease will be reliably identified. However, difficulties arise and variation increases in the detection of “borderline pathology”. There may be a considerable range of inter-observer variance, especially for the mild pathology that is often seen in surveys, and in situations where lesions are regressing.

Variance can be reduced by strict adherence to the protocols, including the consistent positioning of probes, and also by a careful choice of the measurements to be made, concentrating on those that can be precisely described. For example, the protocol for *S. mansoni* now gives a more precise definition of how and where to measure the wall thickness of branches of the portal vein. In the protocol for *S. haematobium*, fissures of the renal pelvis 1 cm long or less are no longer included among the pathological signs, despite the fact that they may represent an early sign of damage. Variance in the observations of one investigator seeing the same patient on different occasions (intra-observer variance) appears to depend on the experience of the observer. It should be improved by careful training.

Even when everything possible has been done to reduce variance, it will still exist, and every survey using ultrasound study should include assessments of inter-observer and intra-observer variance. This quality control should cover a representative sample of at least 10% of all subjects examined and all aspects of the examination.

The results of measurements are influenced not only by the observer but by the equipment used, especially the type of transducer, so the equipment used must always be precisely described in all reports. Data assessing this as a potential source of variance are not yet available.

## Standard protocols for ultrasound examination: *S. haematobium*

The lesions to be investigated in urinary schistosomiasis – the presence of intravesical masses and thickening of the bladder wall, dilatation of the ureter, and hydronephrosis – proved to be relatively easy to observe. Calcification of the bladder wall is a pathognomonic sign, but can not always be detected in early stages, since tiny calcifications may not produce distal shadowing.

It was decided that only minor changes were needed in the protocols for investigating pathology due to *S. haematobium* infection. Fissures of the renal pelvis 1 cm wide or less are no longer to be recorded as pathological, even though they may sometimes represent an early stage of hydronephrosis. Ideally, a second examination should be made after the bladder has been voided. Attention was drawn to the fact that in pregnant women there may be some ambiguity in the interpretation of findings. Pregnancy should always be recorded, and considered as a factor in evaluating dilatation of the renal pelvis and ureters (Richter et al. 1996).

### *Scores for morbidity due to S. haematobium*

Pathological changes due to *S. haematobium* infection can be divided clearly into those affecting the urinary bladder, and those affecting the upper urinary tract. For each of these groups of lesions, an intermediate score is calculated. The urinary bladder intermediate score is given for changes which are specific, but do not necessarily represent very severe morbidity. It shows whether schistosomiasis is absent, only suspected or clearly present. The upper urinary tract intermediate score assesses the

lesions which are associated with severe morbidity and have an unfavourable prognosis, especially hydronephrosis. These lesions are therefore weighted more heavily. However, they are not specific for schistosomiasis, so this score must always be related to the intermediate score for the urinary bladder. Since the two intermediate scores assess different aspects of the disease, both should always be reported. For some purposes, such as the comparison of levels of morbidity between communities, a global score or index of severity obtained by adding the two intermediate scores is also useful. (Part 2, page 20)

### **Standard protocols for ultrasound examination: *S. mansoni***

The investigations recommended in the White Paper Report of 1991 were designed to assess periportal fibrosis, portal hypertension (dilatation of the portal and splenic veins and porto-systemic collaterals) and enlargement of the liver and spleen. In practice, the standardization of some of the suggested procedures proved to be difficult, especially in early or mild infections, owing to the complexity of the portal tree and the variable location of lesions.

Two new concepts for the standardization of data collection were introduced:

1. An additional method for assessing periportal fibrosis is proposed, comparing the observed liver texture with a series of standard reference patterns. Studies evaluating the alternative approaches are already under way, and when more experience has been gathered using both the new and the original procedures it will be possible to decide on the minimum series of observations necessary to give reliable results.
2. Measurements of organ size and vein diameter should be height-adjusted, using standard reference measurements for healthy members of the same population group.

#### *Periportal fibrosis*

Periportal fibrosis is easily identified at the advanced stage when life-threatening haemorrhage might occur as a result of the rupture of oesophageal varices, but in its early stages, periportal fibrosis is difficult to detect and quantify reliably. The quantification of mild pathology was discussed in detail in the workshop.

There are two methods in use for assessing periportal fibrosis. One is a descriptive method, which takes into account the liver texture as a whole (Homeida et al. 1988, Doehring et al. 1989). The other is a quantitative method, involving the measurement of the thickness of the walls of branches of the portal vein (Abdel-Wahab et al. 1992).

The workshop participants did not reach a consensus about which of the two methods is best for evaluating the degree of periportal fibrosis. The quantitative method, given in the 1991 White Paper report, has proved difficult to use in practice and has therefore been revised. The qualitative method is quick to use, but has the disadvantage that it is not always easy to distinguish normal from abnormal findings, and there is major observer-related variance. Therefore, the present White Paper gives protocols for both. It is recommended that both methods should be used until sufficient experience is available to decide on a new standardized protocol.

For the qualitative method, standardized images are provided for comparison, so that numerical scores can be given. For the quantitative method, more explicit guidance about the measurement points to be used on the walls of the periportal vessels has been given. In addition, it is strongly recommended that the values for the diameter of the portal vein and the wall thickness of the portal branches should be adjusted for the subject's height (see below)

### *Organometry*

The size of the liver, the spleen and the portal vein can be measured by ultrasonography. However, the degree of enlargement of an organ can only be accurately assessed by comparison with values for healthy people in the same area and ethnic group. At present, there is not enough data providing such reference values. Until organometric data is available for every endemic area, normal values obtained in a community in Senegal where schistosomiasis is not endemic are given as a reference (Annex C). Results should be related to the subject's height and compared with standard values before interpretation.

Secondly, in many endemic areas concurrent infections may be present that also affect organ size. For example, malaria also causes splenomegaly. It is now recommended that the measurement of spleen size should not be carried out in areas where malaria is present.

### *Indices of severity for S. mansoni*

The methods used to assess the level of pathological change in *S. mansoni* infection do not provide directly comparable results, so that scores for individual lesions cannot be added to give one global score (Thomas et al.1997). Therefore it is suggested that for *S. mansoni*, three scores should be reported: an Image Pattern (IP) score reflecting abnormalities in liver texture; a Periportal Thickening (PT) score, and finally a Portal Hypertension (PH) score for signs of increase in portal pressure.

## **1.4 RECOMMENDATIONS FOR CONTROL PROGRAMMES**

### **General aspects**

Each form of human schistosomiasis has distinct characteristics with regard to its epidemiology and the efficacy of treatment. Knowledge about the dynamics of pathological change obtained using ultrasonography allows recommendations to be made for strategies that will reduce morbidity effectively.

Control of morbidity requires initial treatment and subsequent retreatment. Infected individuals should be treated as soon as they are diagnosed, whatever their age. Praziquantel should be available in health centres for the treatment of symptomatic patients.

The periodicity of treatment and retreatment should be decided after considering the following characteristics of the situation in the area concerned:

- the initial endemic level and the intensity of exposure
- the number of previous mass treatments
- other control measures undertaken in parallel, and their effectiveness.

Assessment of morbidity and its development or regression over time, using ultrasonography, should be an integral part of all control programmes. The evaluation can be carried out by means of regular examination of a sentinel group. Monitoring at intervals of less than 6 months is not necessary.

The results should be applied to decisions on treatment and retreatment strategies, and disseminated for the benefit of other programmes.

Since ultrasonography is relatively expensive, and requires specialised equipment and personnel, it is unlikely to be feasible on a large scale for all control programmes. Therefore clinical examination, and the use of indirect indicators of morbidity, like egg counts, will remain important. It is essential to continue to validate these indicators against direct observation using ultrasound. Standardization of the methodology is also important here, especially for clinical examination, as discussed in Section 1.3.

Quality control must be an integral part of all surveys, for clinical examinations as well as ultrasonography. 10% of examinations need to be tested for inter-observer variance.

### **Recommendations for control programmes: *S. haematobium***

The following recommendations are based on observations of the resolution of pathology after praziquantel therapy and its resurgence after infection, carried out in Tanzania and Ghana (Hatz et al.1998, Wagatsuma et al 1999).

- In a control programme, the first retreatment should be carried out at least a year after the first treatment. Even in hyperendemic areas, where reinfection is likely to occur rapidly, serious pathological changes are not observed within 12 months.
- As the control programme advances, the intervals between treatments may be lengthened on the basis of evaluation, in particular using ultrasonography.
- Generally, retreatment should concentrate on children and adolescents.

### **Recommendations for control programmes: *S. mansoni***

In an area of high transmission, a single mass treatment is not sufficient to reduce morbidity to an acceptable level (Homeida et al.1996). Treatment must be repeated after one year to achieve a significant regression of morbidity, and especially of periportal fibrosis. The time intervals for subsequent retreatment will depend on the criteria outlined above.

Retreatment is strongly recommended for people under 20 years of age, although retreatment of all individuals is desirable. Treatment of symptomatic cases at health facilities should be part of the strategy.

## **1.5 PRIORITIES FOR FUTURE RESEARCH**

### **General**

- a. Organometric values for healthy individuals must be established in all endemic areas for different ethnic groups, as a function of height and gender. The possible effects of other diseases endemic in the area must be considered.
- b. The relationship between pathology revealed by ultrasound and other indicators of morbidity (including newer ones such as biochemical or serological markers) should continue to be explored, since the use of other indicators is likely to reduce costs. Possible indicators include not only clinical and parasitological measures, but also perceived morbidity.
- c. The long-term effects of chemotherapy on pathology due to schistosomiasis (resolution and resurgence of pathology) need to be evaluated in order to improve treatment strategies
- d. Further studies are needed to identify 'non-responders' to treatment - individuals within communities in whom pathology does not regress.
- e. The development of morbidity in new endemic foci and in the course of epidemics needs to be further evaluated.
- f. Geographical variation in morbidity should be studied.
- g. The role of ultrasonography in evaluating pathology of female and male reproductive organs should be established.
- h. Local reference values for uterus-size (corpus- and cervix-) and adnex-size as a function of height, phase of sexual development, parity and intra-uterine fetal growth are needed. (These figures would also be useful for gynaecological and obstetric practice).

- i. The influence of schistosomiasis on fetal growth should be evaluated.
- j. A catalogue of images of unusual pathology for the different schistosome species should be established, and a network set up for the exchange of these among researchers.
- k. It should be assessed whether *S. intercalatum* infection is accompanied by organ abnormalities detectable by ultrasound.

#### **Research priorities for *S. haematobium***

- a. The impact of urinary tract lesions on renal function and mortality needs to be evaluated.
- b. The possibility of urinary schistosomiasis leading to liver abnormalities observable by ultrasonography was discussed in Cairo in 1990. More studies are still needed. The new standard protocol for liver examination proposed for *S. mansoni* could be used
- c. A connection between bladder cancer and schistosomiasis has been postulated in some endemic areas. This should be further clarified.

#### **Research priorities for *S. mansoni***

- a. The two methods for the evaluation of periportal fibrosis should be used in parallel, to provide data on which to base future decisions about the best procedure.
- b. Normal organometric values for people of different heights must be established (in each endemic region and ethnic group) for the sizes of the liver, the spleen, and the portal vein and its main branches. A simple mathematical formula or a computer programme to make the calculation of height-adjusted values easier would be valuable.
- c. The long-term effects of chemotherapy on hepatic fibrosis should be further evaluated.
- d. The value of conventional and Doppler ultrasonography for revealing portal hypertension and monitoring anti-hypertensive treatment has to be validated further.
- e. Different methods for the treatment of advanced periportal fibrosis (medical, endoscopic, interventional or surgical) need to be critically assessed and compared in controlled randomised trials.
- f. Clinical examinations should be standardized. Ultrasonography may be helpful in assessing the reliability of clinical examinations.
- g. The predictive value of intestinal wall thickening seen by ultrasound for schistosomiasis related intestinal pathology in endemic areas needs to be determined.
- h. The ultrasonographic features that indicate a risk of gastrointestinal haemorrhage need to be established and compared with results obtained by Doppler-ultrasound examination. Once the value and limitations of ultrasound in predicting the risk of variceal bleeding have been established, stratification of patients according to the bleeding risk, to enable a rational choice of treatment strategies, may become possible (Richter et al 1998).

#### **Research priorities for *S. japonicum* and other Asian species**

- a. A further meeting to review standardization of ultrasound methodology in Asian schistosomiasis is necessary.
- b. The influence of viral hepatitis on the ultrasonographic features of pathology related to *S. japonicum* infection should be assessed.
- c. The role of ultrasonography in further study of the relationship between liver cancer and schistosomiasis, with or without concomitant viral hepatitis, should be examined.
- d. The long-term effects of chemotherapy on hepatic fibrosis should be evaluated.

## 1.6 CONCLUSIONS

The Niamey workshop gave experts the opportunity to review the work done using the standard protocols for ultrasound examinations in schistosomiasis established in Cairo in 1990 and to consider ways in which the protocols could be further improved.

Ultrasound examination has been successfully used to show that in *S. haematobium* infection, pathological changes resolve rapidly after chemotherapy and do not reappear for a period of at least one year. In *S. mansoni* infection, the regression of periportal fibrosis was found to be slow, but it did occur, especially in young subjects and those with only a moderate level of initial infection. In both cases, retreatment one year after mass treatment could be recommended.

The protocols for *S. haematobium* and *S. mansoni* infection were revised, to improve the standardization of data collection, processing and comparison. In addition, a system of individual scores was introduced, defining positive, negative and suspect cases. These scores should be useful for other workers in community health who need to use the data to assess the level of morbidity in a given setting.

The *S. haematobium* protocol needed little modification. That for *S. mansoni* was found to need considerable revision, especially in the methods for the evaluation of periportal fibrosis. The new protocols include two methods for field testing, so that sufficient data can be collected for an evaluation of which procedures are most reliable in practice.

It is important that the standard methods should be discussed and revised again. The ultimate aim is to produce a set of protocols that will produce reliable, reproducible results in an examination that can be carried out in a short time. It is therefore essential to define those measurements which provide really valuable information, and can be used routinely to provide data on which the effort to control schistosomiasis can be based.

Ultrasound can make a valuable contribution to the monitoring of control programmes, and the data collected should enable informed decisions to be made about where resources can best be invested in measures to reduce morbidity. Criteria should be formulated for the best ways of using ultrasound in control programmes to fulfil these needs.



## **PARTICIPANTS IN THE NIAMEY WORKSHOP**

ABDEL-WAHAB, Professor M. F., Dept. of Tropical Medicine, Faculty of Medicine Kaser El-Aini, Cairo University, P.O. Box 1, Cairo, Egypt

DOEHRING, Professor E., Board of Public Health, Gesundheitsamt, Neustaedter Str. 44, 16 816 Neuruppin, Germany

GARBA, Dr A., Centre de Recherche sur les Méningites et les Schistosomiasés (CERMES), B. P. 10887, Niamey, Niger

HAMMOU, Professor A., Service de radiologie, Hôpital d'Enfants, Place Bab Saadoun, 1007 Tunis, Tunisia

HATZ, Dr C., Swiss Tropical Institute, Socinstrasse 57, 4002, Basel, Switzerland  
(Representative of WHO)

HOMEIDA, Professor M. M. A., The Academy of Medical Sciences and Technology, P. O. Box 12810, Khartoum, Sudan

KARDORFF, Dr R., Medizinische Hochschule Hannover, Children's Hospital, Department of Paediatrics II, 30623 Hannover, Germany

MAGAK, Dr P. W., Division of Vector Borne Diseases, P. O. Box 20 750, Nairobi, Kenya

MBAYE, Dr A., PDRS/Volet Bilharziöse, Région Médicale, B. P. 519, Saint Louis, Sénégal

OLVEDA, Dr R. M., Research Institute for Tropical Medicine, Department of Health, Alabang, Muntinlupa City, Philippines

QURASHI, Professor M. A., Faculty of Medicine & Health Sciences, Omdurman Islamic University, P. O. Box 382, Omdurman, Sudan

RAMAROKOTO, Dr C. E., Institut Pasteur de Madagascar, B. P. 12774, Antananarivo, Madagascar

RICHTER, Dr J., Out-Patients Department (OPD) for Tropical Diseases, Faculty of Medicine, Clinics for Gastroenterology, Hepatology and Infectious Diseases, Heinrich Heine Universität, Moorenstrasse 5, D-40225 Düsseldorf., FR Germany.  
(In 1996; Institute of Tropical Medicine, Berlin, Germany)

TRAORÉ, Dr M., Institut National de Recherche en Santé Publique, Division Santé Communautaire, B. P. 1771, Bamako, Mali

WAGATSUMA, Dr Y. TES Inc, International Division, 3-29-6 Hongo, Bunkyo-ku, Tokyo 113, Japan

ZHONGDAO, Dr W., Jiangxi Provincial Institute of Parasitic Diseases, Nanchang, Jiangxi 33 00 46, Jiangxi Province, P. R. China

### Secretariat

CAMPAGNE, Dr G., CERMES, B.P. 100887, Niamey, Niger

Participants from the Ministry of Public Health, Niger

ALLAROU, Dr A., Projet de lutte contre la bilharziose urinaire dans la vallée du fleuve Niger, B. P. 111, Tillabéri, Niger

BARÉ, Mr I., Direction de l'Hygiène et de l'Assainissement, Ministère de la Santé Publique, Niamey, Niger

Members of the CERMES Organizing Committee

BOULANGER, Dr D.

CHIPPAUX, Dr J. P.

Secretariat of WHO/TDR, Geneva

BERGQUIST, Dr N.R., TDR

REMME, Dr J. H. H., TDR

**SATELLITE SYMPOSIUM: ULTRASONOGRAPHY IN METHODOLOGY  
IN *S. MANSONI* INFECTION**

**6th International Symposium on Schistosomiasis, Belo Horizonte, Brazil Oct, 19-24, 1997**

**PARTICIPANTS**

BARATA, Dr C.H.A., Hospital Escola da Faculdade de Medicina do Triangulo Mineiro, Uberaba, Brazil

DOMINGUES, Dr A.L.C., Hospital das Clínicas, Recife, Universidade Federal do Pernambuco, Brazil

GERSPACHER-LARA, Dr R., Faculdade de Medicina, Universidade de Minas Gerais, Belo Horizonte, Brazil

LAMBERTUCCI, Professor J. R., Faculdade de Medicina, Universidade Minas Gerais, Belo Horizonte, Brazil

PINTO DA SILVA, Dr R. A., Faculdade de Medicina, Universidade Minas Gerais, Belo Horizonte, Brazil

RICHTER, Dr J., OPD Tropical diseases, Faculty of Medicine, Clinics for Gastroenterology, Hepatology and Infectious Diseases, Heinrich Heine Universität, Moorenstrasse 5, D-40225 Düsseldorf., FR Germany

SENA ROCHA, Dr R., Centro de Pesquisa 'René Rachou', Fundação Oswaldo Cruz, Belo Horizonte, Brazil

Observers

PRATA, Professor, A., Hospital Escola da Faculdade de Medicina do Triangulo Mineiro, Uberaba, Brazil

BERGQUIST, Dr N.R., WHO/TDR.

Organizing Committee

TELES RABELLO, Dr A.L., Centro de Pesquisa 'René Rachou', Fundação Oswaldo Cruz, Belo Horizonte, Brazil

DOS SANTOS CARVALHO, Professor O., Centro de Pesquisa 'René Rachou', Fundação Oswaldo Cruz, Belo Horizonte, Brazil

**Acknowledgements**

The editors wish to thank Klaus Bocionek for the image patterns for the liver in Annex A. The organometric tables and graphs in Annex C were supplied by Rüdiger Kardorff.

The encouragement and support of the late Dr K.E. Mott are gratefully appreciated. He played a big role in the initiative resulting in this report.



## BIBLIOGRAPHY

- Abdel-Wahab MF et al. Grading of hepatic schistosomiasis by the use of ultrasonography. *Am J Trop Med Hyg*, 1992, 46: 403-408
- Abul-Khair MH et al. Sonography of bilharzial masses of the scrotum. *J Clin Ultrasound* , 1980, 8 : 239-240
- Bahakim HH, Hussain S, Al Sulaimini SH. Ultrasonography of pancreatic masses: a case report. *J Trop Med Hyg*, 1990, 89: 81-84
- Cairo Working Group. The use of diagnostic ultrasound in schistosomiasis - attempts at standardization of methodology. In Hatz C, Jenkins JM, Tanner M. (eds.) Special Issue: Ultrasound in Schistosomiasis. *Acta Tropica*, 1992, 51: 45-63
- Cerri GG, Alves VAF, Magalhaes A. Hepatosplenic schistosomiasis *mansoni*: ultrasound manifestations. *Radiology*, 1984, 153: 777-780
- Dittrich M et al. Preliminary ultrasonographical observations of intestinal lesions in a community with heavy *S. mansoni* infection in Richard Toll, Senegal. *Acta Tropica*, 1994, 58: 331-336
- Doehring-Schwerdtfeger E et al. Sonomorphological abnormalities in Sudanese children with *Schistosoma mansoni* infection. A proposed staging system for field diagnosis of periportal fibrosis. *Am J Trop Med Hyg*, 1989, 41: 63-69
- Doehring-Schwerdtfeger E et al. Inter-observer variance in ultrasonographical assessment of *Schistosoma mansoni*-related morbidity in young schoolchildren. *Acta Tropica*, 1992, 51: 85-88
- Eltoum IA et al. Liver ultrasonography in an area endemic for schistosomiasis heamatobium. *Am J Trop Med Hyg*, 1993, 48: 77-81
- Emanuel A et al. Ecocardiografia na hipertensão pulmonar esquistossomótica. *Revista da Sociedade Brasileira de Medicina Tropical*, 1987, 20: 115-117
- Hatz C, Jenkins J.M, Tanner M. (eds) *Ultrasound in Schistosomiasis*. Special issue: *Acta Tropica* , 1992, 51: 1-97. Includes comprehensive reviews of the use of ultrasound in schistosomiasis.
- Hatz C, Odermatt P, Urbani C. Preliminary data on morbidity due to *Schistosoma mekongi* infections among the population of Sdau village, Northeastern Cambodia. *Report of Médecins sans frontières*, 1996, Phnom Penh.
- Hatz C et al. Evolution of *Schistosoma haematobium*-related pathology over 24 months after treatment with praziquantel among school children in Southeastern Tanzania. *Am J Trop Med Hyg* , 1998, 59 : 775-781
- Homeida MMA et al. Diagnosis of pathologically confirmed Symmers' periportal fibrosis by ultrasonography: a prospective blinded study. *Am J Trop Med Hyg*, 1988, 38 : 86-91
- Homeida MA et al. The effectiveness of annual vs. biennial mass chemotherapy in reducing morbidity due to schistosomiasis: a prospective study in Gezira-Managil, Sudan. *Am J Trop Med Hyg*, 1996, 54 : 140-145
- Lambertucci JR et al. Acute Manson's schistosomiasis: sonographic features. *Trans Roy Soc Trop Med Hyg*, 1994, 88 : 76-77
- Lutz H & Meudt R. Urogenital system. In: Manual of Ultrasound. (Lutz H. and Meudt R. eds.) *Berlin: Springer Verlag*, 1984, 88-99.
- Mostafa MH, Badawi AF, O'Connor PJ. Bladder cancer associated with schistosomiasis. *Parasitology Today*, 1995, 11: 87-89
- Nafeh MA et al. Ultrasonographic changes of the liver in *Schistosoma haematobium* infection *Am J Trop Med Hyg*, 1992, 47: 225-230.

Nooman ZM et al. The use and limitations of ultrasonography in the diagnosis of liver morbidity attributable to *S.mansoni* infection in community-based surveys. *Mem. Inst Oswaldo Cruz*, 1995, 90 : 147-154

Ohmae H et al. Ultrasonographic and serologic abnormalities in *Schistosoma japonicum* infection in Leyte, The Philippines. *Am J Trop Med Hyg*, 1992, 46 : 89-98

Richter J et al. Transabdominal ultrasound for the diagnosis of *Schistosoma haematobium* infection of the upper female genital tract: a preliminary report. *Trans Roy Soc Trop Med Hyg*, 1995, 89 : 500-501

Richter J et al. Sonographic screening for urinary tract abnormalities in patients with *Schistosoma haematobium* infection: pitfalls in examining pregnant women. *Bulletin of the World Health Organization*, 1996, 74 : 217-221

Richter J et al. Sonographic prediction of variceal bleeding in patients with liver fibrosis due to *Schistosoma mansoni*. *Tropical Medicine and International Health*, 1998, 3 : 728-735

Thomas AK et al. Evaluation of ultrasonographic staging systems for the assessment of *Schistosoma mansoni* induced hepatic involvement. *Acta Tropica*, 1997, 68 : 347-356

Vilana R et al. Schistosomiasis of the male genital tract: transrectal sonographic findings. *J.Urol.*, 1997, 158 : 1391-3

Wagatsuma Y et al. Resolution and resurgence of *S. haematobium*-induced pathology following community-based chemotherapy in Ghana as detected by ultrasound. *Journal of Infectious Diseases*, 1999, 176 : 1515-1522

*Future use of new imaging technologies in developing countries. Report of a WHO Expert Committee.* Geneva, World Health Organization , 1985 (WHO Technical Report Series, No. 723)

*Meeting on the use of ultrasound for assessment of pathology due to schistosomiasis*, October 1-4, 1990, Cairo, Egypt. World Health Organization, UNDP/World Bank/WHO Special Programme for Research and Training in Tropical Diseases, 1991, TDR/SCH/ULTRASON/91.3

*Manual of diagnostic ultrasound.* World Health Organization, 1995, Palmer PES (ed.) WHO

Yazdanpanah Y et al. Organometric investigations of the spleen and liver by ultrasound in *S. mansoni* endemic and non-endemic villages in Senegal. *Am J Trop Med Hyg*, 1997, 57: 245 - 249

Yi Z-s, Huang L-x, Wong M-k. Diagnostic atlas of ultrasound for schistosomiasis japonicum. Hunan Institute of Parasitic Diseases, Yueyang , WHO Collaborating Centre, 1992, Hunan, China.

## **PART 2: INVESTIGATION OF PATHOLOGY DUE TO *S. HAEMATOBIIUM***

### **2.1 METHODOLOGY**

#### **Equipment**

Sector scanners or curved array transducers are preferable to a linear probe for the assessment of the urinary bladder and the kidneys.

*The type of equipment used should always be mentioned when reporting the results.*

#### **Preparation: bladder filling**

Adequate bladder filling is essential to assess shape and wall irregularity. If the bladder is not well filled, the normal appearance of the wall structure may be interpreted as pathological.

*Fluids must be given 30 minutes - 1 hour before examination.*

*Diuretics are not indicated.*

*If any abnormality of the kidney and/or ureters is observed, a post-voiding examination of these organs should be done 30 min. – 1 hour later. Record results of post-voiding examination.*

#### **Recording of pregnancy**

Pregnancy may interfere with exploration of the upper urinary tract. Even in the first trimester, pregnancy-related dilatation of the upper urinary tract may occur. Dilatation of the kidney pelvis in pregnancy may be physiological. Pregnancy also has implications for therapy.

*A glance at the uterus shows whether a woman is pregnant.*

*Pregnancy must always be assessed and noted on the record-forms (NB; this information must be kept confidential!)*

*In calculating results, pregnant women must be considered as a separate group.*

#### **Standard views**

1. *Transverse view of the bladder.*

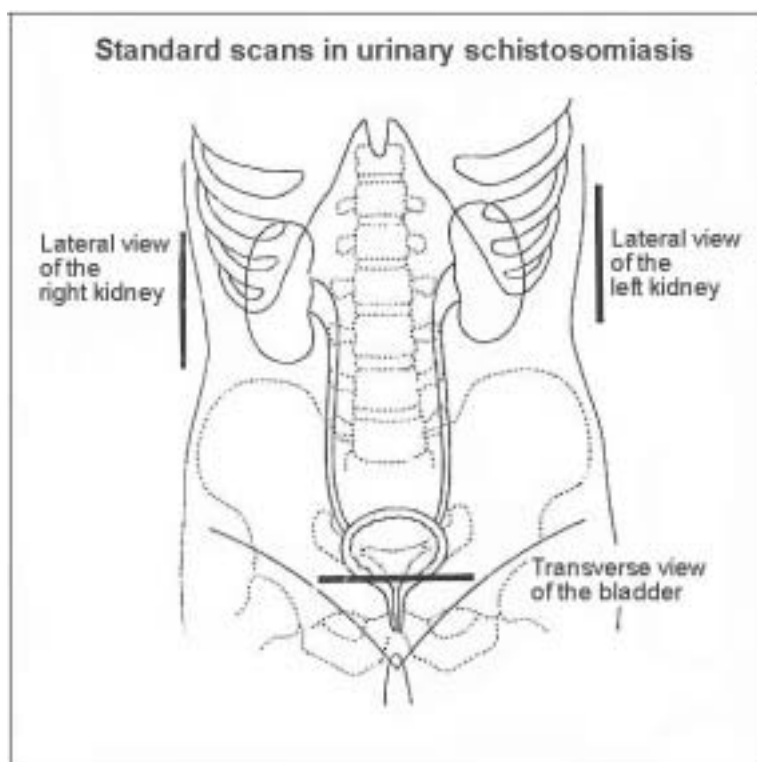
Place the probe above the pubic symphysis at the maximal cross-sectional diameter of the bladder with a view of the distal part of the ureters.

If residual urine is to be measured (additional examination) a longitudinal section will also be needed. Measure width, depth and length.

- 2 + 3 *Left and right lateral views (longitudinal section)*

Observe both kidneys and the proximal part of the ureters from a lateral view in the mid-axillary line. If this is not possible use a dorsal view.

Distal and proximal parts of the ureters should be followed as far as possible.



## 2.2 INTERMEDIATE AND GLOBAL SCORES

Only those lesions observed in the standard examinations are considered. (See also Part 1 page 7)

**Urinary bladder intermediate score:** Indicates presence or absence of schistosomiasis:

- 0 – 1 schistosomiasis unlikely
- = 2 schistosomiasis likely
- ≥ 3 schistosomiasis very likely

Upper urinary tract intermediate score

This score is related to severity of morbidity and lesions which indicate an unfavourable prognosis (but see note on pregnancy, above)

**Global individual score**, or index of severity, is the sum of these two scores.

## 2.3 MODULE 1: STANDARD INVESTIGATIONS; DEFINITIONS AND SCORES

### 2.3.1 Urinary bladder

**Shape:** A deviation from the normal rectangular shape of the well-filled bladder indicates pathology.

- 0 = normal (rectangular)
- 1 = rounded (distorted)

#### **Bladder wall**

*Irregularity* of inner surface of the bladder wall. Wall irregularity with thickening up to 5 mm is recorded as irregularity. Multifocal lesions are present when two or more lesions are separated by a normal wall.

- 0 = absent
- 1 = focal
- 2 = multifocal or diffuse

*Wall thickening*: the thickness of the posterior bladder wall should be measured at the posterior wall in the area of the trigonum. The normal thickness of the wall is  $\leq 5$  mm.

- 0 =  $\leq 5$  mm (normal)
- 1 =  $>5$  mm, focal
- 2 =  $> 5$  mm, multifocal or diffuse

*Masses*: a localized thickening of the bladder wall protruding into the lumen ( $>10$  mm). A score of 2 is given for one mass. If there are more, add the total number of masses (e.g. for 3 masses, score is  $2 + 3 = 5$ ).

- 0 = none
- 2 = single
- $n + 2$  = multiple (where  $n$  = total number of masses)

*Pseudopolyps*: an outgrowth of the wall, attached by a slender base (narrower than the mass), is defined as a pseudopolyp. Distinction from a mass is not always evident when the base or pedunculum is not well visualized. Pseudopolyps are scored in the same way as masses.

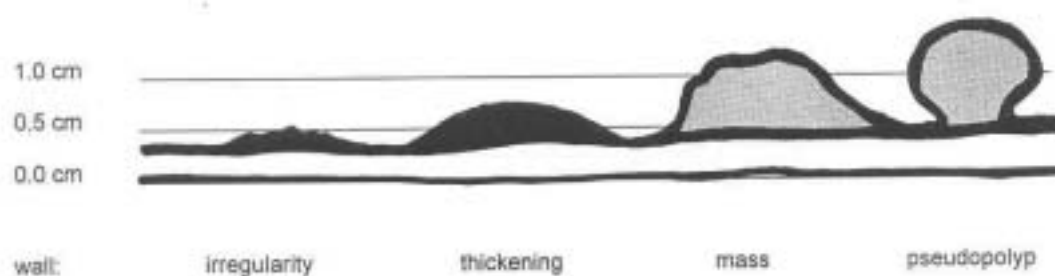
- 0 = none
- 2 = single
- $n + 2$  = multiple (where  $n$  = total number of pseudopolyps)

Presence of several lesions in one subject

The bladder may have different lesions in different parts of the wall. The observer must decide in which category to place each one; for example whether it is a wall thickening or a mass, and record and score it in the chosen category.

➔ ***Each lesion should be recorded and scored only once, in one category only!***

**Classification of schistosomiasis-related bladder lesions**



### 2.3.2 Ureters

Dilatation of each ureter is recorded separately.

0 = absent, ureter is not visualized

3 = dilated, the ureter is visualized at the proximal and/or distal third

4 = grossly dilated, the ureter is dilated more than is required for mere visualization.

### 2.3.3 Kidneys

Dilatation is measured as the largest anechoic separation of the central echogenic complex (fat inside renal pelvis) in a horizontal axis.

The stage of hydronephrosis of each kidney is recorded.

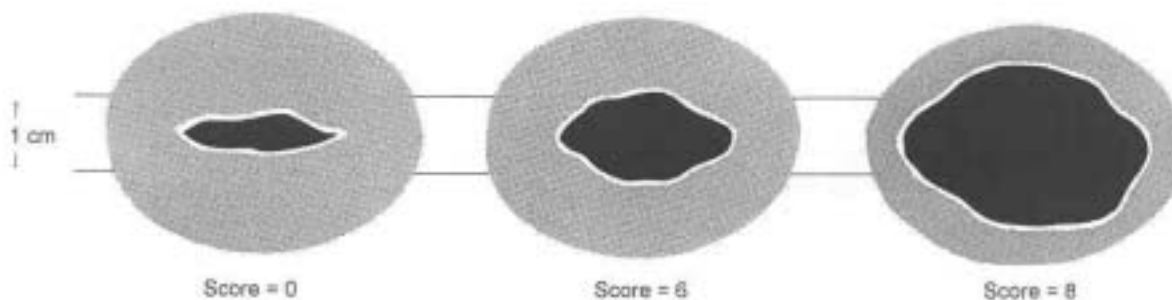
0 = not dilated, or fissure  $\leq 1$  cm present

6 = moderate dilatation with conserved parenchyma  
(distance between renal pelvis and capsula  $> 1$  cm)

8 = severe dilatation with compression / absence of parenchyma  
(distance betw. renal pelvis and capsula  $< 1$  cm)

#### Measurement of congestive dilatation of the renal pelvis

##### Renal longitudinal scan



## 2.4 MODULE 2: ADDITIONAL INVESTIGATIONS; DEFINITIONS AND SCORES

### 2.4.1 Urinary Bladder

#### Wall calcification.

Although almost pathognomonic of the disease, calcification may only be clearly seen (with conical shadow) in advanced cases.

0 = not visible

1 = visible

#### Residual urine

Can be observed if the bladder is re-examined after voiding.

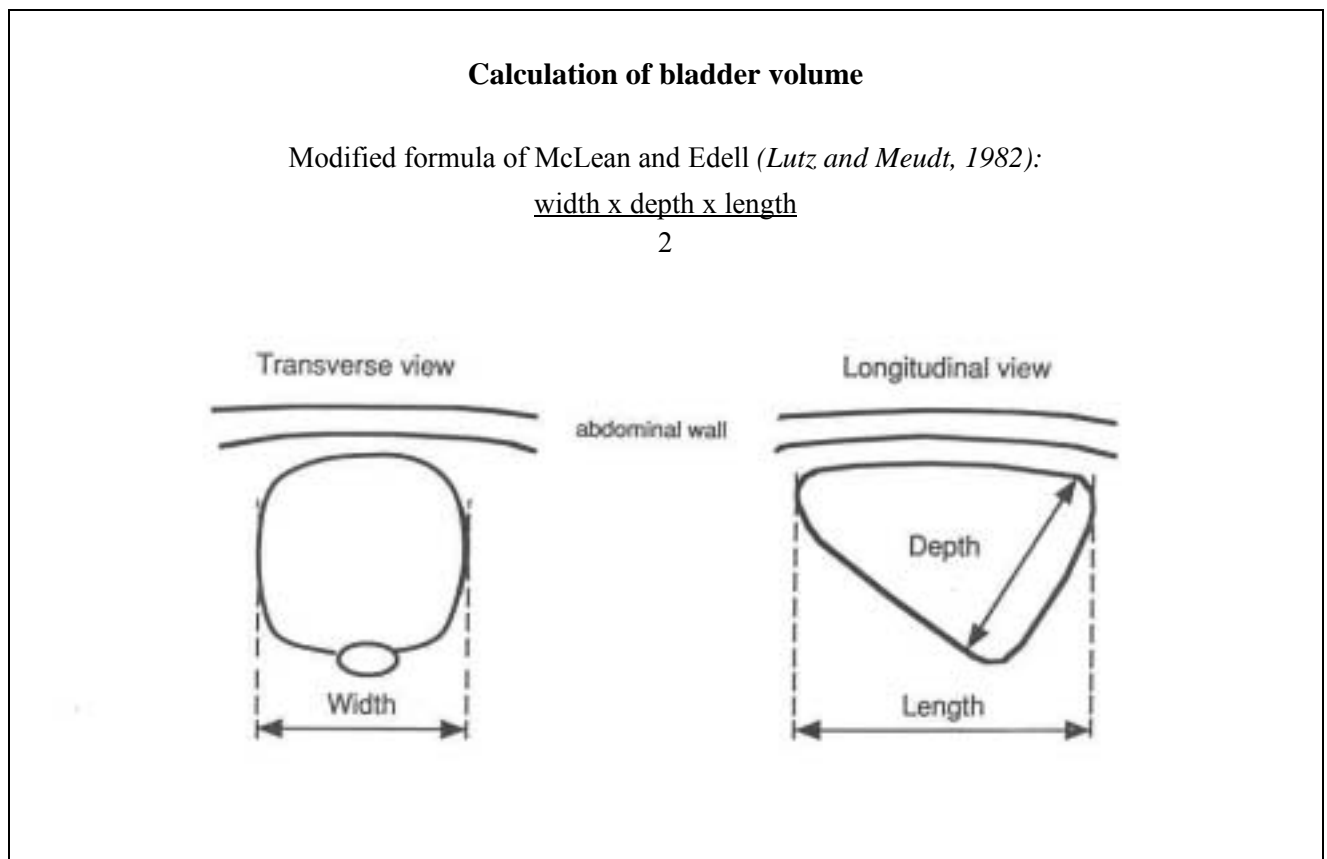
To calculate the volume, measure the bladder dimensions before and after voiding and calculate the pre-and post-voiding volumes.

Residual urine is present when > 10% of the pre-voiding urine is found on post-voiding examination.

0 = absent

1 = present

*NB: if the bladder was grossly distended before voiding residual urine will always be found*



#### **2.4.2 Kidney: fibrosis of the pylon**

Echodense structures along the borders of the pylon (occur in adults only).

0 = absent

1 = present

#### **2.4.3 Liver: pathological changes**

Examination should be carried out as described for *S. mansoni* infection.

## 2.5 FORMS FOR RECORDING RESULTS

Record sheet for <i>S. haematobium</i> associated ultrasound findings		page 1
Name, other names		
Patient number		
Date of examination ( day/month/year)		
Age / Year of birth		
Sex: (if female: is she pregnant? yes: <input type="checkbox"/> → consider separately <input type="checkbox"/> not pregnant)		Female <input type="checkbox"/> Male <input type="checkbox"/>
Ultrasound transducer used: convex <input type="checkbox"/> sector <input type="checkbox"/> linear <input type="checkbox"/>		Height cm
MODULE 1 - STANDARD EXAMINATION		
Urinary bladder		Score
Shape normal (rectangular) = 0 round (distorted) = 1		
<b>Bladder wall: record each lesion observed in <u>one</u> of the following categories</b>		
Wall irregularity (inner surface, thickening ≤ 5 mm) No = 0 focal = 1 multifocal / diffuse = 2		
Wall thickening (>5mm, ≤10 mm) No (≤ 5 mm) = 0 focal = 1 multifocal / diffuse = 2		
Mass (>10mm) (do not record as wall irregularity or focal thickening at the same time!) no = 0 single = 2 multiple: number of masses (=n)+2		
Pseudopolyp (do not record as wall irregularity, thickening or mass at the same time!) no = 0 single = 2 multiple: number of pseudopolyps (=n) + 2		
<b>Urinary bladder intermediate score</b>		
Ureters		
Right ureter not visualized = 0; dilated; visualized at proximal and / or distal third = 3 grossly dilated and /or entirely visualized = 4		
Left ureter not visualized = 0; dilated; visualized at proximal and / or distal third = 3 grossly dilated and /or entirely visualized = 4		
Renal pelvis (if dilated , record only after voiding)		
Right pelvis not dilated, fissure ≤ 1cm = 0 moderately dilated; parenchyma thickness ( 1-sided) > 1 cm = 6 marked hydronephrosis; parenchyma compressed: thickness < 1cm = 8		
Left pelvis not dilated, fissure ≤ 1cm = 0 moderately dilated; parenchyma thickness ( 1-sided) > 1 cm = 6 marked hydronephrosis; parenchyma compressed: thickness < 1cm = 8		
<b>Upper urinary tract intermediate score</b>		
<b>Final <i>S. haematobium</i> score</b>		



Record sheet for <i>S. haematobium</i> associated ultrasound findings		page 2
Name, other names		
Notes		
Patient number		
Date of examination ( day/month/year)		
Ultrasound transducer used:    convex <input type="checkbox"/> linear <input type="checkbox"/> sector <input type="checkbox"/>		Height _____ cm
Age / Year of birth		
Sex		female <input type="checkbox"/> male <input type="checkbox"/>
Height (cm)		
MODULE 2 - ADDITIONAL INVESTIGATIONS		
<b>Calcifications of bladder wall</b> Not detected = 0    detected = 1		
<b>Residual urine</b> To measure residual urine, assess bladder width ( <b>W</b> ), length ( <b>L</b> ) and depth ( <b>D</b> ) before and after voiding and calculate volumes:		
<i>Bladder dimensions before voiding (cm)</i> W =    L =    D =		Bladder volume 1 (ml) $\frac{W \times L \times D}{2} =$ _____
<i>Bladder dimensions after voiding (cm)</i> W =    L =    D =		Bladder volume 2 (ml) $\frac{W \times L \times D}{2} =$ _____
<i>Residual urine = Post-voiding volume as % of prevoiding volume</i>		$\frac{\text{Bladder volume 2}}{\text{Bladder volume 1}} \times 100 =$ _____ %
<b>Residual urine score</b> absent = 0    present (>10%) = 1		
<b>Fibrosis of renal pelvis</b> <i>Right kidney</i> not detected = 0    detected = 1		
<i>Left kidney</i> not detected = 0    detected = 1		
<b>Liver pathology</b> Protocol as for <i>S. mansoni</i> infection		



## **PART 3: INVESTIGATION OF PATHOLOGY DUE TO *S. MANSONI***

### **3.1 METHODOLOGY**

#### **Equipment**

Linear, convex or sector transducers may be used to assess pathology of the liver, spleen and abdominal vessels.

Visualisation is usually easier with a convex or sector probe.

Measurements are more accurate using a linear probe.

The protocol must always state which probe was used.

#### **Preparation**

The subject should have fasted for at least 4 hours before the examination.

*For the sequence of investigations to be performed see the flow-chart on page 37.*

## **Standard views**

### ***Views to be performed routinely:***

#### ***1. Longitudinal liver scans***

##### ***1a Left parasternal longitudinal view***

With the abdominal aorta as reference, measure the left liver lobe from the upper to the caudal margin in the left parasternal line (PSL). This view is similar to the one used to demonstrate paraumbilical and coronary vein collaterals.

##### ***1b Right mid-clavicular view.***

Used to assess the size of the right liver lobe in the right midclavicular line (MCL).

##### ***1c Right anterior axillary view:***

The probe should be placed vertically, in a section through the right kidney as reference.

This view is used to assess the echogenicity of the liver parenchyma by comparing it with the echogenicity of the kidney. A normal liver in children and adolescents is slightly less echogenic than the kidney, whereas in adults it is slightly more echogenic than the kidney parenchyma. If present, ascites can be seen with this view.

Used to assess the size of the right liver-lobe.

#### ***2. Substernal transverse view***

Used to assess the shape of the left liver lobe and to detect the coronary vein. This is one of the views particularly useful for comparing the liver appearance with an image pattern.

In this view the peripheral portal branches of second order emerging from the left portal branch are visualised.

#### ***3. Subcostal transhepatic view***

The probe should be placed below the right costal margin and directed cephalad.

This view is used to assess the liver surface and parenchyma appearance, to detect deviation of hepatic veins, and to measure periportal wall thickening of the peripheral branch.

This is another view that is particularly useful for assigning an image pattern to the picture of the liver parenchyma.

#### ***4. Right oblique view***

The point of reference should be where the maximum diameter of the portal vein is seen. Usually the diameter of the portal vein is measured at this position. Portal vein measurements must be performed with the patient quietly breathing, avoiding forced inspiration (Valsalva's manoeuvre).

#### ***5. Left intercostal oblique view***

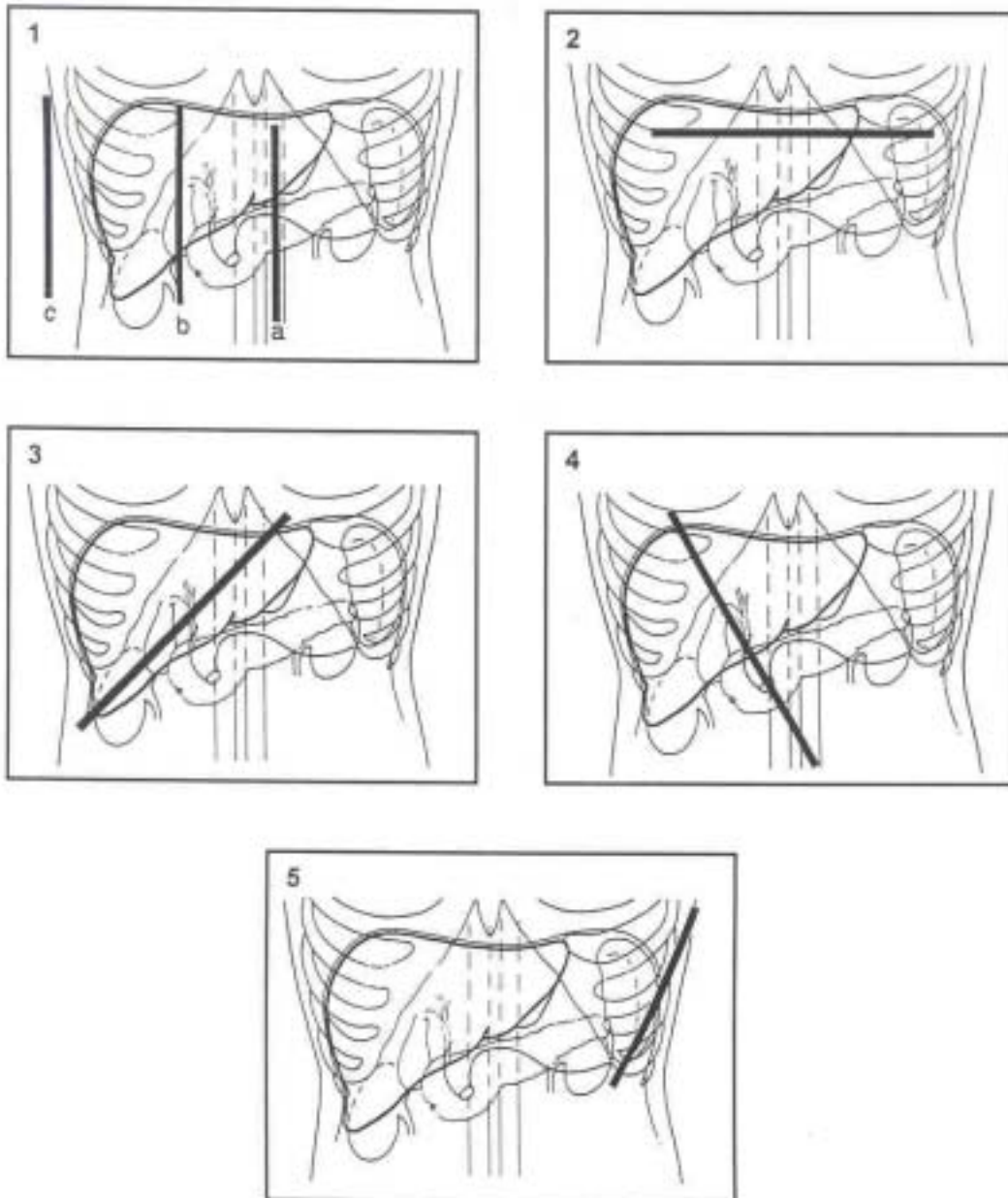
The probe is placed in a section through the splenic hilus as the point of reference. Splenic varices are visualized in this view.

The probe is then adjusted until the major longitudinal diameter of the spleen is seen. When splenomegaly is present, spleen length usually exceeds the dimensions of the transducer. In such cases, spleen length can be assessed by marking the upper tip on the patient's abdomen, then moving the transducer downwards until the lower tip is visualised. The distance between these points can then be measured with a measuring-tape.

#### ***6. Examination of gall-bladder***

The best position for examining the gall-bladder varies. Most frequently it is seen in view 1b. It should be demonstrated in its longitudinal section to assess shape, filling state and wall thickness. When gall-bladder abnormalities are found, subjects may need to be reexamined after fasting for 8 hours.

**Standard scans for liver examination**



1. Longitudinal liver scans

- 1a Left parasternal longitudinal view
- 1b Right mid-clavicular view.
- 1c Right anterior axillary view

2. Substernal transverse view

3. Subcostal transhepatic view

4. Right oblique view

5. Left intercostal oblique view

### 3.2 IMAGE PATTERN OF LIVER PARENCHYMA → IP SCORE

The picture of the liver is compared with the standard image patterns in Annex A

**If the liver appears normal ( Pattern A)**

*No further examination is necessary.* score = 0

**If any echogenic periportal thickening is observed**

*The observed image is classified and score allocated* score = 1 – 8

#### **Classification of images**

If some degree of periportal thickening is observed, the image pattern in the liver parenchyma is compared with the patterns shown in Annex A. The examiner sums up the pictures taken in the different standard sections and assigns them to the standard patterns shown. In some cases, a combination of patterns may be present. This reflects the presence of both peripheral and central abnormalities. A combination of patterns may be assigned.

#### Mixed image patterns related to schistosomiasis

All combinations of patterns B-F are permissible, e.g. D+C, D+C+B or E+C.

In very advanced cases (F) peripheral pathology is frequently conglomerated with other changes and is no longer discernible.

#### Image patterns not known to be related to *Schistosoma mansoni* infection

Other conditions may also cause abnormal liver patterns (see Table and Annex A)

Pattern X :observed in several diseases e.g. chronic hepatitis of various etiologies, or liver cirrhosis.

Pattern Y : seen especially in fatty liver or liver infiltration.

Pattern Z : all other types of pathology (abscesses, cysts, tumours etc)

#### Mixed pathology

Periportal thickening may occur in association with other abnormal liver findings (e.g. X + B). Such cases must be considered separately. No score is given even if one of the patterns B – F is also present.

It is important to note that ultrasonography never provides a histological diagnosis. Ultrasound results are usually interpreted within the clinical context.

#### **Assignment of an IP score**

A score from 1 – 8 is assigned as shown in Table 1

If several patterns are present, the score given is that of the pattern with the highest score.

If patterns X – Z are present, no score is given, even if one of the patterns B – F is also observed.

**Table 1**

**Liver Parenchyma patterns and IP scores**

Pattern	Picture	IP-Score
A	Normal structure	0
<i>Patterns observed in schistosomiasis</i>		
B	' <u>Starry sky</u> ' ( diffuse echogenic foci)	1
C	Highly echogenic ' <u>ring echoes</u> ', which correspond to the ' <u>pipe stems</u> ' seen in a scan perpendicular to the one where rings are seen	2
D	Highly echogenic ' <u>ruff</u> ' around portal bifurcation and main stem	4
E	Highly echogenic ' <u>patches</u> ' extending* expanding? from the main portal vein and branches into the parenchyma	6
F	Highly echogenic ' <u>bands</u> ' and ' <u>streaks</u> ' , extending from the main portal vein and its bifurcation to the liver surface, where they retract the organ surface. (Note: echogenic thickening of ligamenta alone does not justify assignment of the sonographic image to this pattern.)	8
Cb Dc, Db, Dcb Ec, Eb, Ecb Fc	Schistosomiasis-related combined patterns	2 4 6 8
<i>Patterns indicating pathology different from periportal fibrosis. If these are present, no score is given.</i>		
X	Diffusely coarse liver texture, irregular liver surface, distorted hepatic veins, rounded caudal liver edge	-
Y	Diffusely increased liver echogenicity, loss of highly reflective edges of peripheral portal branches, possibly distal sound extinction, rounded caudal liver edge	-
Z	All other liver abnormalities, specify	-

### **3.3 PERIportal THICKENING (PT) SCORE AND LIVER SIZE**

#### **3.3a Periportal Thickening (PT) score**

##### **If the liver appears normal**

score = 0

*No further examination is necessary.*

##### **If liver parenchyma shows indications of periportal fibrosis**

*Assign a preliminary PT score of 1*

score = 1

*Continue the examination*

##### **Measure the thickness of the walls of the second order portal branches,**

i.e. the first segmental branches leaving the left or right branch of the main portal vein.

##### **Where should measurements be made?**

Follow the main portal wall to where it divides into left and right branches.

Follow the left (or right) branch by turning the transducer in its axis until the first segmental branches leaving this branch are seen ( see annex B).

Measurements are taken at the point where walls are thickest, but otherwise as close as possible to the first branching point where the segmental branch leaves the major portal branch.

##### **Which vessels should be measured, and how many ?**

Measure the walls of two first-order segmental portal branches out of the left portal branch vein.

If possible, measure a third tributary branch of the right portal branch. Sometimes it might be difficult to be sure whether the branch to be measured is a tributary (side-) branch or the continuation of the main stem of the branch. A tributary branch is preferable, but wall thickness is expected not to vary too much between the two, if the measurement is done peripherally to the second branching point.

##### **How should the measurements be made ?**

1. Measure external (outer to outer) diameter
2. Measure lumen (inner to inner) diameter
3. Subtract lumen diameter from external diameter.

This gives a value for the combined thickness of the vessel walls at the point where the measurements were made.

##### **Calculation and scoring of wall thickness**

Calculate the mean wall thickness (both walls) for the two (or three) vessels measured.

To decide on the score, adjust results for body height by comparing the mean thickness with the reference table (Annex C):

normal range	2 SD or less above mean	score = 0
increased	> 2 SD but $\leq$ 4 SD above mean	score = 3
much increased	> 4SD above mean	score = 7

*This gives the intermediate PT score*

##### **Calculate the final PT score**

Add the preliminary PT score to the intermediate PT score.

This gives a final PT score in the range 1 (1 + 0) to 8 (1 + 7)

### 3.3b Liver size and non-specific liver abnormalities

A number of organometric and other parameters are also considered important for the study of schistosomiasis, and should be assessed and recorded.

A scoring system is given for data analysis purposes, but since some of the abnormalities are not specific for schistosomiasis, the scores are not included in the final score. For details of liver scans see pages 30-31.

**Liver surface:** A deviation from the normal smooth appearance of the liver surface (subcostal view, posterior margin) indicates liver pathology: Enlargement of the left liver lobe is usually accompanied by a "wavy" surface.

Smooth	score = 0
Slight irregularity	score = 1
Gross irregularity	score = 2

**Caudal liver edge:** Deformation of the caudal liver edge is another non-specific sign of liver pathology. A normal caudal liver edge is convex (ventral surface) / concave (dorsal surface). A convex posterior surface and a rounded caudal margin are indicators of morbidity.

Sharp (convex-concave caudal liver edge)	score = 0
Smooth (bi-convex caudal liver edge)	score = 1

**Liver size:** The size of both liver lobes should be recorded routinely. It is not included in the final score because variations are non-specific and not necessarily related to schistosomiasis. In periportal fibrosis the liver may be enlarged, normal or shrunken, depending on the stage of liver fibrosis and on particular regional conditions (nutrition etc.)

**Left lobe:** The length from the cranial to the caudal edge of the liver should be measured in a longitudinal section in the left parasternal line (PSL), i.e. 2 cm left from the xyphoid. As reference the aorta is visualized dorsally to the liver. The length measured is then adjusted to the height of the individual (see Annex C). A score is given according to the degree of enlargement:

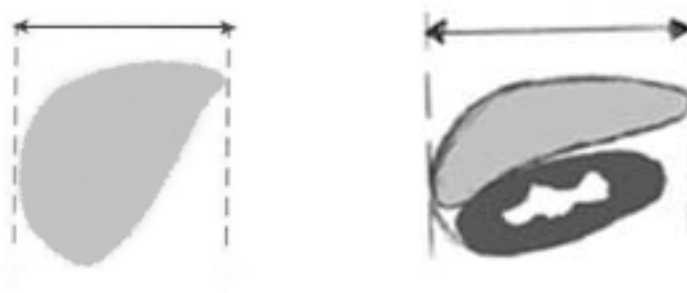
Not enlarged	= mean plus $\leq 2$ SD	score = 0
Enlarged	= increase $> 2$ SD, but $\leq 4$ SD	score = 1
Much enlarged	= increase $> 4$ SD	score = 2

#### Right lobe

The length of the right liver lobe is measured in the right anterior axillary view. The normal dimensions in adults and children are related to height (annex B3). A decrease in size is reported as shrinking.

Normal	= size within $\geq 2$ SD of mean	score = 0
Shrunk	= size $< 2$ SD but $\geq 4$ SD below mean	score = 1
Severely shrunk	= size $> 4$ SD below mean	score = 2

#### Measurement of liver lobe size



### 3.4 PORTAL HYPERTENSION SCORES

*Parameters which indicate an increase in portal hypertension are an increase in the diameter of the portal vein, changes in collateral veins or the presence of ascitic fluid in the abdomen.*

#### 3.4.1 Portal vein diameter

Measure the internal (inner to inner) diameter of the portal vein at the entry point of the portal vein into the liver. Adjust the value for height by comparing it with reference values (Annex C).

Assign a Portal Vein score:

Normal	increase 0 to $\leq 2$ SD	score = 0
Dilatation	increase 2 to $\leq 4$ SD	score = 4
Marked dilatation	increase $>4$ SD	score = 6

#### 3.4.2 Collateral veins

*Portal hypertension is indicated by the presence of the following:*

presence of splenohilar varices, a splenorenal shunt, the coronary vein (synonyms: *vena coronaria ventriculi*, *vena gastrica dexter* or *sinister*, left / right gastric vein), size 4mm or larger, gastro-oesophageal, pancreato-duodenal varices or an entirely recanalized paraumbilical vein:

<i>Portal hypertension</i>	<i>Normal findings</i>
splenic vein varices	not detected
coronary vein (= left/right gastric vein) $\geq 4$ mm	$< 4$ mm
gastro-oesophageal collaterals	not detected
patent paraumbilical vein	not detected or umbilical vein only partly patent, and $< 3$ mm
splenorenal collaterals	not detected
pancreato-duodenal collaterals / duodenal varices	not detected

**Assign a Collaterals score:** no collateral vessel detected score = 0  
collaterals detected score = 4

#### 3.4.3 Ascites (free fluid in abdomen)

**Assign an Ascites score :** no free fluid detected in abdomen score = 0  
ascites present score = 3

#### 3.4.4 Calculate the final Portal Hypertension (PH) score

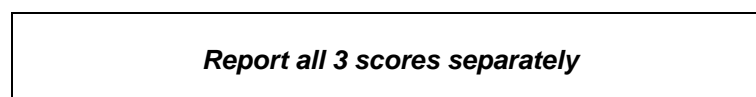
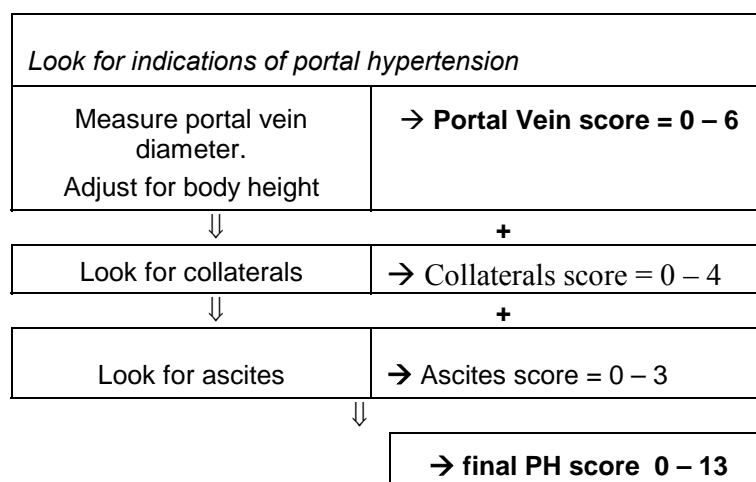
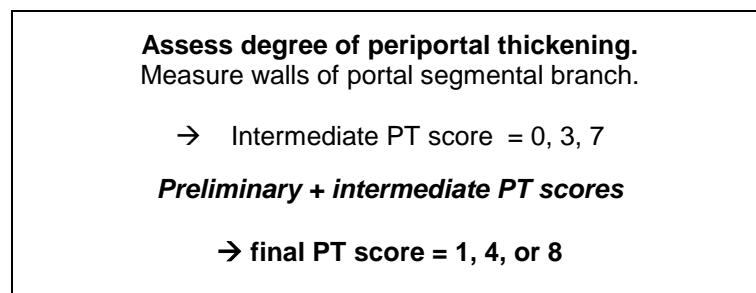
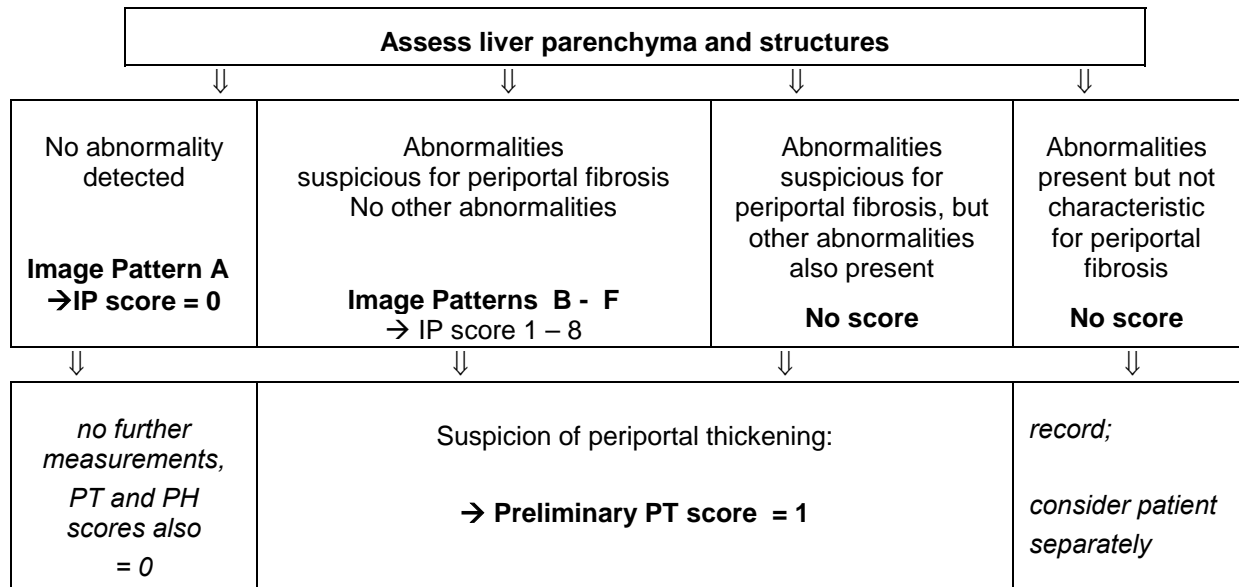
This is the sum of the above three scores:

	Portal vein score	0 – 6
+	Collaterals score	0 – 4
+	Ascites score	<u>0 – 3</u>
=	<b>Portal Hypertension score</b>	<b>0 – 13</b>

0 = portal vein not dilated, no collaterals, no ascites

13 = marked portal vein dilatation + presence of collaterals + ascites

### 3.5 SEQUENCE OF EXAMINATIONS AND SCORING PROCEDURE



### 3.6 INTERPRETATION OF THE FINAL SCORE

The table below suggests an interpretation of the three final scores in terms of disease severity.

Whereas patients without any abnormalities, as well as with advanced abnormalities are easily classified, interpretation is more difficult with patients who present with borderline abnormalities. The proportion of these cases depends not only on the cohort studied, but also on the methodology used.

The likelihood of periportal fibrosis increases with increasing scores. When the liver picture corresponds to patterns E and F (IP score 6,8) it can safely be assumed that periportal fibrosis is present. The same applies to PT scores of  $\geq 4$

IP score	PT score	PH score	Interpretation
0	0	0	No sign of periportal fibrosis
1	1	0	Incipient periportal fibrosis not excluded
2	1	0	Periportal fibrosis possible
4	1	0	Periportal fibrosis probable
2	4, 8	0	Periportal fibrosis
4	4, 8	0	Periportal fibrosis
6	(1,) 4, 8	0	Advanced periportal fibrosis
8	(1,) 4, 8	0	Advanced periportal fibrosis
4 – 8	(1,) 4, 8	3 -13	Advanced periportal fibrosis + portal hypertension

### 3.7 ADDITIONAL INVESTIGATIONS

#### Spleen

The spleen is measured in a left oblique view.

Measure the maximum length in a section through the splenic hilus.

Adjust measurement for body height of the individual (annex B3).

- 0 = splenomegaly absent (  $\leq$  mean + 2 SD)
- 1 = moderate splenomegaly ( size > 2 to  $\leq$  4 SD above mean)
- 2 = marked splenomegaly ( > 4 SD above mean)

*Note: In malarious areas, the spleen may be enlarged in the absence of schistosomiasis.*

#### Gall-bladder wall

Ideally, for examination of the gall-bladder the subject should have fasted for at least 8 hours, but a 4-hour fast is acceptable when the gallbladder wall is found to be less than 4 mm thick.

Measure the anterior wall (adjacent to the liver) is measured where it is parallel to the transducer surface, in order to avoid erroneous inclusion of the adjacent intestinal wall in the measurement.

A post-prandially contracted gall-bladder has a small or even invisible luminal cavity and a thick wavy wall consisting of two layers with different echogenicity. Echo-poor or normoechoic wall thickening may be observed in a variety of conditions (acute cholecystitis, hepatitis, hypoproteinaemia, ascites irrespective of its cause). Tenderness under ultrasound guided palpation (ultrasonographic Murphy sign) reveals inflammation.

Schistosomiasis-related gall-bladder wall thickening is usually painless and leads to echodense wall thickening, sometimes with external echogenic protrusions.

Contractility of the gall-bladder can be assessed when the volume after a fatty meal is compared to the fasting volume. Gall-bladder function is impaired when postprandial volume reduction is less than 50%.

- 0 = normal ( thickness < 4 mm).
- 1 = increased (thickness  $\geq$  4 mm)



### 3.8 FORMS FOR RECORDING RESULTS

Record sheet for <i>S. mansoni</i> associated ultrasound findings					page 1
Name, other names					
Patient number					
Date of examination ( day/month/year)					
Age / Year of birth					
Sex			Female <input type="checkbox"/> Male <input type="checkbox"/>		
Ultrasound transducer used: Convex <input type="checkbox"/> Linear <input type="checkbox"/> Sector <input type="checkbox"/>			Height: cm		
MODULE 1 - STANDARD EXAMINATION					
Liver 1: Parenchyma (Section 3.2)					
Parenchyma				→ Image Pattern-Score	
No abnormality detected ( pattern A) ⇒ end examination				= 0	
Other abnormalities detected ( patterns X, Y, Z) ⇒ consider separately				No score given	<input type="checkbox"/>
Unable to decide (Image pattern B)				IP-score = 1	
Image Pattern C, Cb				IP-score = 2	
Image Pattern D, Dc, Db, Dcb				IP-score = 4	
Image Pattern E, Ec, Eb, Ecb				IP-score = 6	
Image Pattern F, Fc				IP-score = 8	
<b>Image pattern (IP) score</b>					
Liver 2: Wall thickness of second order portal branches (i.e. first order segmental portal branches (Section 3.3a))				→ Periportal Thickening (PT) Score	
Periportal thickening is suspected ? no = 0 yes = 1				Preliminary PT score	
Periportal wall measurement (external diameter minus lumen ) of 2nd order portal branches					
Diameter (mm)	Vessel 1	Vessel 2	Vessel 3(optional)	Mean of diameters	
External					
Internal					
Difference					
Intermediate PT score based on increase above reference mean (see Annex B): + ≤ 2 SD = +0    +2 SD to ≤ 4 SD = +3    +>4 SD = +7				Intermediate PT score	
<b>Final Periportal Thickening (PT) score (0-8)</b>					




Record sheet for <i>S. mansoni</i> associated ultrasound findings				page 2
Name, other names				
Patient number				
Date of examination ( day/month/year)				
Ultrasound transducer used: Convex <input type="checkbox"/>		Linear <input type="checkbox"/>	Sector <input type="checkbox"/>	Height: _____ cm
MODULE 1 - STANDARD EXAMINATION continuation				
Liver 3: size and other abnormalities (Section 3.3b)				
Surface irregularity	none = 0	slight = 1	gross = 2	
Caudal liver edge	sharp = 0	rounded = 1		
Liver shape in PSL	convex/concave = 0	deformed = 1		
Size of left lobe (PSL)	mm	Score: mean + $\leq 2SD = 0$ $+>2SD - \leq 4SD = 1$ $+>4SD = 2$		
Size of right lobe (AAL)	mm	Score: mean - $\leq 2SD = 0$ $->2SD - \leq 4SD = 1$ $->4SD = 2$		
Liver 4: Assessment of Portal Hypertension (Section 3.4)				→ PH score
Portal vein diameter	mm	Portal vein score (see Annex C) $+ \leq 2 SD$ score = 0 $+>2 SD$ to $\leq 4 SD$ score = 4 $+>4 SD$ score = 6		
Collateral veins	Splenic varices <input type="checkbox"/> Coronary vein $\geq 4mm$ <input type="checkbox"/> Gastro-oesophageal varices <input type="checkbox"/> Pancreatico-duodenal varices <input type="checkbox"/> Entirely recanalized paraumbilical vein ( $\geq 3mm$ ) <input type="checkbox"/> Splenorenal shunt <input type="checkbox"/> Others <input type="checkbox"/>			
		Collaterals score: not detected: score = 0    present: score = 4		
Ascites	Ascites score: not detected: score = 0    present: score = 3			
Portal hypertension (PH) score (0-13)				
Final scores:	IP	PT	PH	

MODULE 2 - ADDITIONAL INVESTIGATIONS				
Spleen length	mm	mean + $\leq 2SD = 0$	$>2SD$ to $\leq 4SD = 1$	$>4SD = 2$
Gallbladder wall thickness	mm	$<4mm = 0$	$\geq 4mm = 1$	

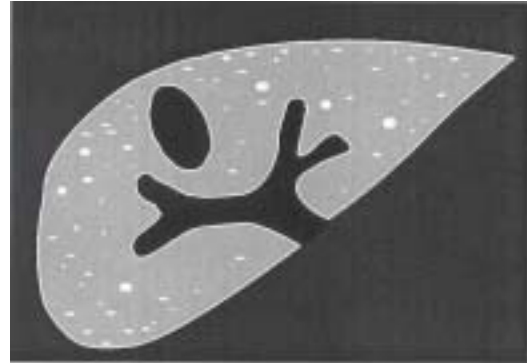


**ANNEX A: IMAGE PATTERNS IN THE LIVER PARENCHYMA, OBSERVED BY ULTRASONOGRAPHY**

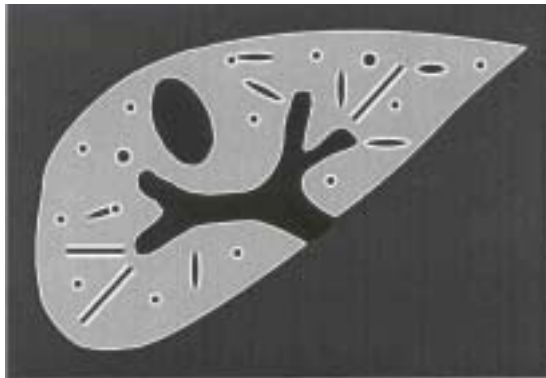
**Patterns associated with schistosomiasis (A – F)**




A : normal



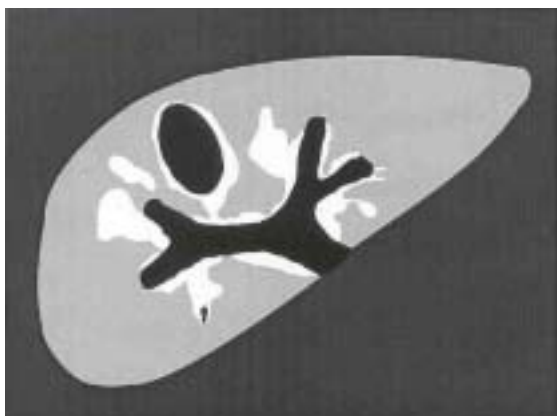B : "starry sky"



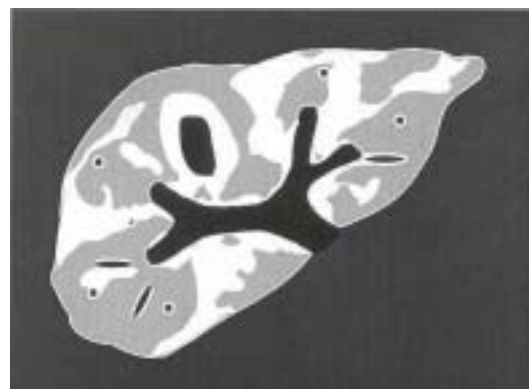
C : "rings and pipe-stems"



D : "ruff" around portal bifurcation



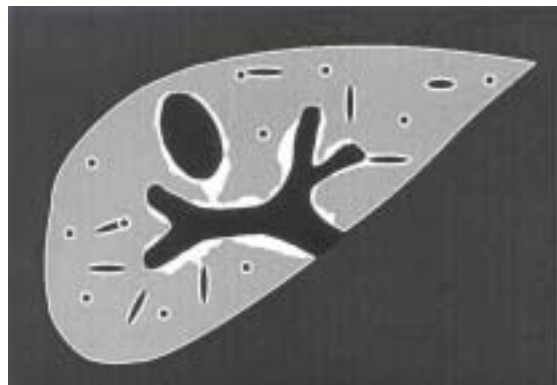
E : "patches"



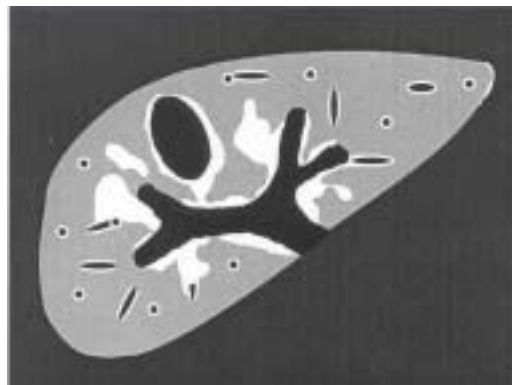
F : "bird's claw"

## ANNEX A: IMAGE PATTERNS IN THE LIVER PARENCHYMA, OBSERVED BY ULTRASONOGRAPHY

### Combined patterns (Dc, Ec)




D c



E c

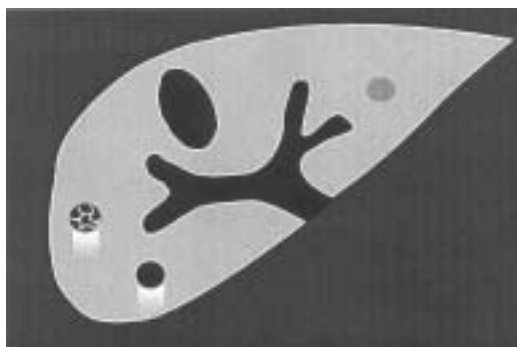
### Patterns not known to be related to schistosomiasis



X : cirrhosis-like

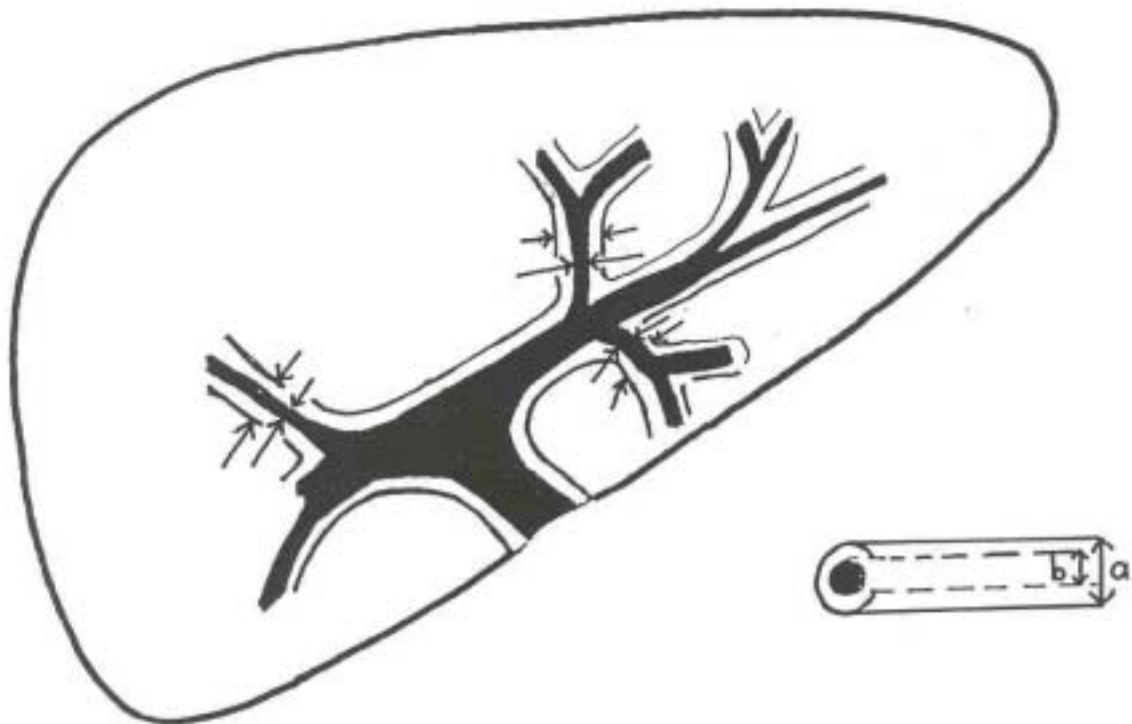


Y : fatty liver-like



Z : other abnormalities

## ANNEX B: MEASUREMENT OF THE DIAMETER OF A SECOND ORDER PORTAL BRANCH



### Measurement of the thickness of the walls of the second order portal branches

i.e. the first segmental branches leaving the left or right branch of the main portal vein.

See also Section 3.3a

Follow the main portal wall to where it divides into left and right branches.

Follow the left (or right) branch by turning the transducer in its axis until the first segmental branches leaving this branch are seen ( see figure).

Measure at the point where walls are thickest, or as close as possible to the first branching point where the segmental branch leaves the major portal branch.

Measure external (outer to outer) diameter

Measure lumen (inner to inner) diameter

### Which vessels should be measured, and how many ?

Measure the walls of two first-order segmental portal branches out of the left portal branch vein.

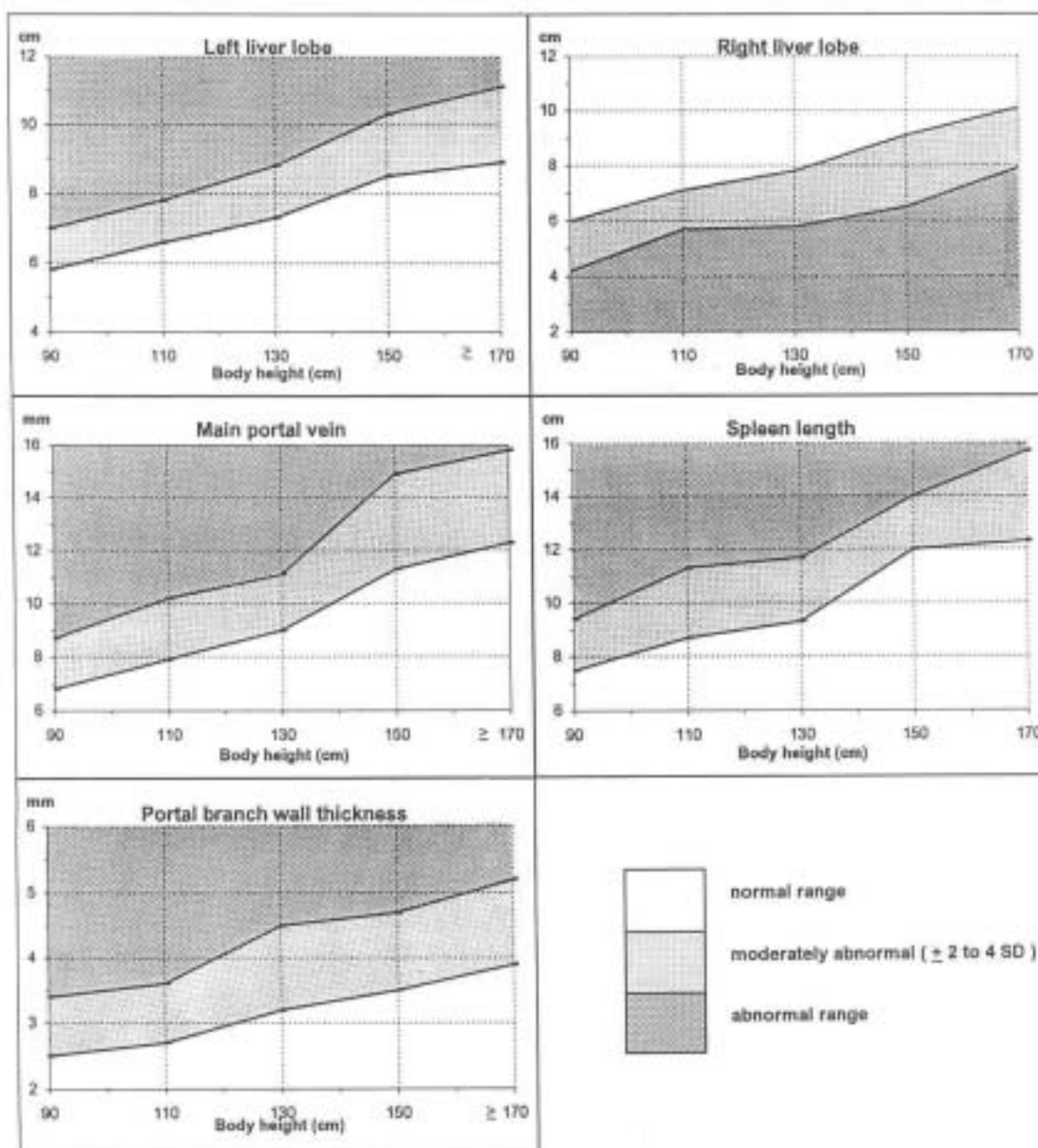
If possible, measure a third tributary branch of the right portal branch.

Note: Sometimes it might be difficult to be sure whether the branch to be measured is a tributary (side-) branch or the continuation of the main stem of the branch. A tributary branch is preferable, but wall thickness is expected not to vary too much between the two, if the measurement is done peripherally to the second branching point.

## ANNEX C: ORGANOMETRY

### Normal ranges for ultrasound organometry adjusted for body height

These values for an African community were obtained in Kathete Gaye, Sénégal, where schistosomiasis is not endemic (Yazdanpanah et al. 1997). They are provided for use until standards are available for other regions and ethnic groups. Obtaining such basic data is a matter of urgency. The graphs were based on a table of values calculated from the raw data of the study (see next page)



Portal branch wall thickness is expressed as the sum of the thickness of both walls at the point of measurement (external diameter minus diameter of lumen).

### Annex C: Organometry; tables used for preparation of graphs

Based on the raw data of Yazdanpanah Y, Thomas AK, Kardorff R et al. (1997).

Body height (cm)	Liver: left lobe **		Liver: right lobe **	
	2 SD	4 SD	-2 SD	-4 SD
80-100	5.8	7.0	6.0	4.2
101-120	6.6	7.8	7.1	5.7
121-140	7.3	8.8	7.8	5.8
141-160	8.5	10.3	9.1	6.5
> 160	8.9	11.1	10.1	7.9

Body height (cm)	Main portal vein ** Inner diameter		Spleen **	
	2 SD	4 SD	2 SD	4 SD
80-100	6.8	8.7	7.5	9.4
101-120	7.9	10.2	8.7	11.3
121-140	9.0	11.1	9.3	11.7
141-160	11.3	14.9	12.0	14.0
> 160	12.3	15.8	12.3	15.7

Body height (cm)	2nd order portal branches wall thickness (total of 2 sides)**	
	2 SD	4 SD
80-100	2.5	3.4
101-120	2.7	3.6
121-140	3.2	4.5
141-160	3.5	4.7
> 160	3.9	5.2

Values show the limits of the:

**Normal range** = mean  $\pm$  2 standard deviations (SD)  
**Moderately abnormal range** = mean  $\pm$  4 standard deviations (SD).

\* Data were recalculated from the raw data of a study performed in Kathete Gaye, Senegal (n = 275; Yazdanpanah Y, Thomas AK, Kardorff R et al. 1997)

\*\* Standard sections and units for organometry:

left liver lobe, longitudinal in sternal line (cm)

right liver lobe, longitudinal in the right anterior axillary line (cm)

main portal vein, oblique view along the axis of the vessel (mm)

spleen, oblique section along the maximum diameter of the organ, through the hilus (cm)

portal branch wall (measured by measuring inner and outer diameter) oblique subcostal view of liver parenchyma (mm); wall thickness is calculated by subtracting the width of the lumen from the overall outer diameter (mm)