

CONRAD/2000.1  
WHO/RHR/00.11

MANUAL FOR THE STANDARDIZATION  
OF COLPOSCOPY FOR THE EVALUATION  
OF VAGINAL PRODUCTS

**UPDATE 2000**

---

CONRAD  
CONTRACEPTIVE RESEARCH  
AND DEVELOPMENT PROGRAM



WORLD HEALTH  
ORGANIZATION

This document is not a formal document of the World Health Organization (WHO). All rights are reserved by CONRAD and WHO but the document may be freely reviewed, reproduced or translated in part or in whole, but not for sale or in conjunction with commercial purposes.

Copies of this document are available on request from:

Contraceptive Research and Development Program (CONRAD)  
1611 N. Kent St., Ste. 806  
Arlington, VA 22209  
USA

Fax: (703) 524-4770  
E-mail: [info@conrad.org](mailto:info@conrad.org)

Department of Reproductive Health and Research  
World Health Organization  
1211 Geneva 27  
Switzerland

Fax: 41 22 791 4189  
E-mail: [rhrpublications@who.int](mailto:rhrpublications@who.int)

© CONRAD and the World Health Organization 2000

CONRAD/2000.1  
WHO/RHR/00.11

MANUAL FOR THE STANDARDIZATION  
OF COLPOSCOPY FOR THE EVALUATION  
OF VAGINAL PRODUCTS

**UPDATE 2000**

---

CO|N|R|A|D

CONTRACEPTIVE RESEARCH  
AND DEVELOPMENT PROGRAM



WORLD HEALTH  
ORGANIZATION



**MANUAL FOR THE STANDARDIZATION  
OF COLPOSCOPY FOR THE EVALUATION  
OF VAGINAL PRODUCTS**

**UPDATE 2000**

**TABLE OF CONTENTS**

INTRODUCTION.....	1
BACKGROUND.....	1
THE ROLE OF COLPOSCOPY.....	2
PROCEDURAL DETAILS.....	4
REVISED PROCEDURE FOR COLPOSCOPY IN THE DEVELOPMENT OF NEW VAGINAL PRODUCTS.....	6
DESCRIPTION OF FINDINGS .....	8
RECORD OF COLPOSCOPIC FINDINGS .....	10
BIBLIOGRAPHY .....	12



## INTRODUCTION

Colposcopy of the vagina and cervix is receiving increasing application in the development of vaginal products. The goal of this type of colposcopy is the detection of epithelial changes that may increase the likelihood of HIV or other STD acquisition. In 1995, the World Health Organization published a manual entitled, "Manual for the Standardization of Colposcopy for the Evaluation of Vaginally Administered Products." In January 1999, the Contraceptive Research and Development Program (CONRAD) and the International Working Group on Microbicides (IWGM), in association with the Joint United Nations Program on HIV/AIDS (UNAIDS) convened a meeting in Washington, D.C., the goals of which were to: 1) review modifications of the WHO procedure that had been tried by various investigators; 2) review findings in women using and not using vaginal products; 3) consider alternatives to colposcopy; and 4) reach consensus on a revised procedure, terms, analysis, and future research. One result is the revised colposcopy procedure described in this updated manual. The procedure involves proper patient positioning, examination of the external genitalia under magnification, speculum examination of the cervix, fornices, and vaginal walls with the naked eye followed by lavage and speculum examination under magnification, and taking samples, as appropriate, for microscopic examination.<sup>1</sup>

## BACKGROUND

Colposcopy is used primarily to detect cancerous and pre-cancerous lesions of the cervix. However, the procedure provides a good light source and magnification, which can facilitate inspection of the vaginal surface as well. In the late 1980s and early 1990s, colposcopy began to be used to examine vaginal and cervical changes seen in studies of vaginal products, specifically spermicides and vaginal rings (Niruthisard 1991, Roddy 1993, Goeman 1995, Bounds 1993). The concern was raised that these changes could predispose a woman to infection, the most worrisome being, of course, HIV.

Before that concern could be addressed, it was necessary to devise a uniform procedure and terminology for carrying out colposcopy of the cervix and vagina in women not suspected of having cervical neoplasia so that findings from one study could be compared with those from another. The original WHO manual was designed to meet this need. The procedure called for examination of the external genitalia, cervix, vaginal fornices, and vaginal walls under low and high power magnification, with and without a green filter, and before and after application of acetic acid.

---

<sup>1</sup> A full report of the workshop proceedings, including a list of the participants, may be found on the CONRAD web site ([www.conrad.org](http://www.conrad.org)) and an abbreviated report in the following publication: Mauck CK, Baker JM, Birnkrant DB, Rowe PJ, Gabelnick HL. The use of colposcopy in assessing vaginal irritation in research: report from a conference. AIDS 2000; 14: (in press).

Findings were to be described using the following criteria: size; site; number; presence of edema, demarcation, peripheral reaction, and slough; and intactness of the epithelium and blood vessels. One of the following terms was to be used for each finding: ulcer, abrasion, ecchymosis, petechial hemorrhage, subepithelial hemorrhage and swelling, erythema, or edema.

Since this uniform procedure became available, a number of studies have been carried out in which colposcopy was used to evaluate the effect of using various products (see bibliography). It became evident from these trials that, because the significance of colposcopic findings is not known, subjecting volunteers to the discomfort and time involved in the original procedure may not be justifiable until the procedure, and the interpretation of its results, are further standardized.

Modifications of the original procedure have been tried by a number of investigators. In general, efforts have been made to simplify and shorten the length of the procedure from 30-40 minutes to 5-10 minutes. Most researchers have eliminated the use of acetic acid and the green filter as neither step is felt to make significantly more findings visible, and acetic acid interferes with the vascular evaluation (although certain protocols may retain acetic acid if, for example, changes associated with HPV are being evaluated). Pap smears and diagnostic tests for STD pathogens and other changes in vaginal flora have been added by some in an effort to correlate colposcopic findings with other cervical/vaginal conditions. Participants in the 1999 colposcopy workshop were able to achieve consensus on a revised version of the original procedure which is included in this manual.

## **THE ROLE OF COLPOSCOPY**

Colposcopy in vaginal spermicide/microbicide research and in the development of mechanical barriers has, as its goal, the detection of epithelial changes in the vagina and cervix caused by the use of vaginal products. The clinical significance of such changes is not known, but it is theorized that they may increase the likelihood of STD/HIV acquisition either via the creation of portals of entry for microorganisms or via recruitment of target cells. Epithelial changes could also cause discomfort.

Factors unrelated to product use, such as age, time in cycle, frequency of intercourse, use of tampons, and the presence of vaginal infections may cause changes in the epithelium. Examples of factors that may affect colposcopic observations are shown in Table 1. In addition, the examiner's experience with pelvic examinations in general and colposcopy in particular will affect his or her ability to bring findings into view and describe them. Red-green color blindness will affect the ability to detect erythema.

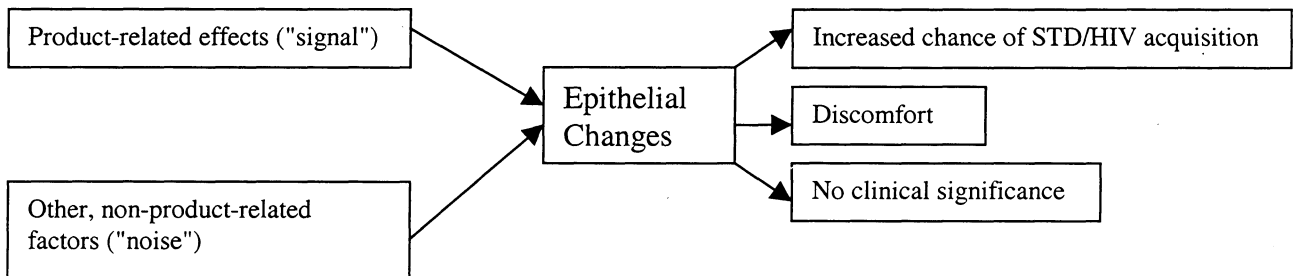
**TABLE 1**  
**FACTORS NOT ASSOCIATED WITH PRODUCT USE**  
**THAT CAN AFFECT COLPOSCOPIC FINDINGS**

<b>FACTORS</b>	<b>EXAMPLES</b>	<b>MECHANISM</b>
Endogenous hormonal factors	<ul style="list-style-type: none"> <li>▪ Age</li> <li>▪ Time in cycle</li> </ul>	Hormonal changes may affect vaginal blood flow and epithelial thickness which in turn will affect the degree of erythema observed.
Exogenous hormonal factors	<ul style="list-style-type: none"> <li>▪ Use of hormonal contraception</li> <li>▪ Use of other steroid products</li> </ul>	Hormonal changes may affect vaginal blood flow and epithelial thickness which in turn will affect the degree of erythema observed.
Anatomical factors	<ul style="list-style-type: none"> <li>▪ Vaginal and cervical dimensions</li> <li>▪ Uterine position</li> <li>▪ Parity</li> </ul>	Anatomical factors and the location of a finding will affect the ease with which it is seen. Whether light falls on it directly or at an angle will affect its appearance.
Mechanical factors	<ul style="list-style-type: none"> <li>▪ Pattern of intercourse and/or masturbation</li> <li>▪ Use of intravaginal products such as tampons, barrier contraceptives, and condoms</li> <li>▪ Speculum injury</li> <li>▪ Stretching and drying of epithelium during examination</li> </ul>	Mechanical stressors before or at the time of the examination may create findings that confound interpretation of those resulting from the new product.
Chemical factors	<ul style="list-style-type: none"> <li>▪ Use of intravaginal products such as spermicides, douches, and other chemical irritants</li> <li>▪ Cigarette smoking</li> <li>▪ Fluids introduced during the examination such as water, saline, or acetic acid</li> </ul>	The use of chemical products other than the one under study may create findings that confound interpretation of those resulting from the new product.
Infections	<ul style="list-style-type: none"> <li>▪ Fungal, e.g. candida</li> <li>▪ Protozoal, e.g. trichomonas</li> <li>▪ Viral, e.g. herpes simplex, human papillomavirus</li> <li>▪ Bacterial, e.g. chlamydia, gonorrhea, syphilis, donovanosis</li> </ul>	Infections may cause changes in blood flow and, therefore, erythema as well as fragility and disruption of the epithelium and blood vessels. Whether HIV has an effect on the epithelium is not known.

In studies in which the goal is to detect epithelial changes that are the result of product use, the

presence of epithelial changes that are not the result of product use can confound the results and lead to the unwarranted discontinued development of an otherwise promising product. Product-related changes may be likened to "signal" and non-product-related changes to "noise" (Figure1). A diagnostic procedure that best separates "signal" from "noise" is most desirable. Attaining this requires: 1) knowledge of factors which, when seen, may be attributed to product use ("signal"); 2) knowledge of all factors not associated with product use that can affect the cervical/vaginal epithelium ("noise") - this may include variability between observers; 3) knowledge of the epithelial changes which, regardless of their cause, either increase the likelihood of HIV acquisition or cause symptoms by themselves; and 4) knowledge of the best method to detect product-related, clinically significant epithelial changes. Attaining this knowledge requires a colposcopic procedure that is simple enough to be used in developing country settings, is objective enough to provide reproducible observations, and can produce data in a form suitable for appropriate statistical analysis.

**FIGURE 1**



### **PROCEDURAL DETAILS**

The term "colposcopy" should be understood to mean magnified visualization of the vagina and cervix. Use of a colposcope, per se, is not necessary as long as the following criteria are met by whatever technique is used:

- a) Ability to magnify at 4 to 10X;
- b) Self-contained (integrated) light source;
- c) Binocular or monocular optics; and
- d) Ability to photodocument findings, if possible. (Photographs or other pictorial records should be calibrated to permit comparison of records obtained at different centers and using different magnification factors.)

The research colposcopy procedure to be used should be standardized at an investigators' meeting that precedes the start of the study. The people carrying out the colposcopy examinations in

preliminary research studies must have experience in colposcopy in general and must demonstrate, prior to the start of the study, that they have competence in the research colposcopy procedure specified in the protocol. In later research studies, in addition to having investigators with the required experience in colposcopy at the centers taking part in the research, someone should also be appointed to take responsibility for the overview of the colposcopy being carried out during the study.

In all studies, data should be collected on the number of findings, their location, size, and type, whether they persist or progress, and, if applicable, the effect of dose. Findings should be tallied by subject and should include categorization by location and type of finding.

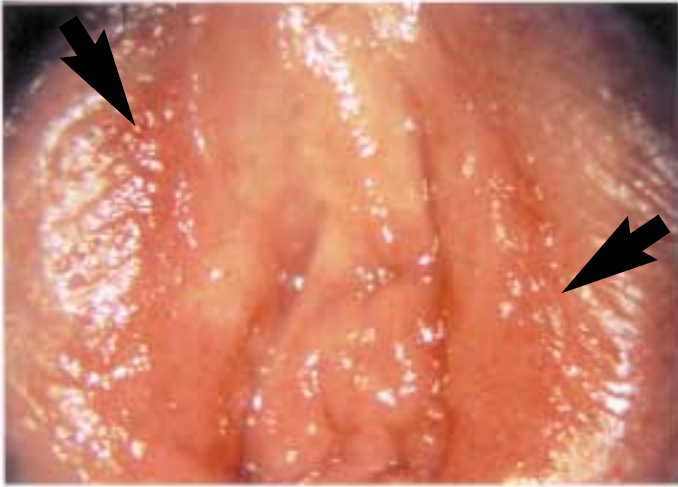
When a finding involves more than one anatomical area, the percent of each anatomical area that is occupied by the finding should be recorded. This is preferred over recording the percent of a finding that may be found in each of the anatomical areas. For example, it is felt to be more informative to record that a finding involved half of the anterior cervical trunk and one third of the anterior fornix than to record that two thirds of the finding was located on the anterior cervical trunk and one third of it on the anterior fornix. Findings involving more than one anatomical area should be included in the tallies of each area, recognizing that the resulting tallies of anatomical areas, when taken together, will add up to more than the tally of individual findings made regardless of location. Very small findings (e.g. petechiae) should be grouped and recorded as the area covered by the group.

**REVISED PROCEDURE FOR COLPOSCOPY  
IN THE DEVELOPMENT OF NEW VAGINAL PRODUCTS**

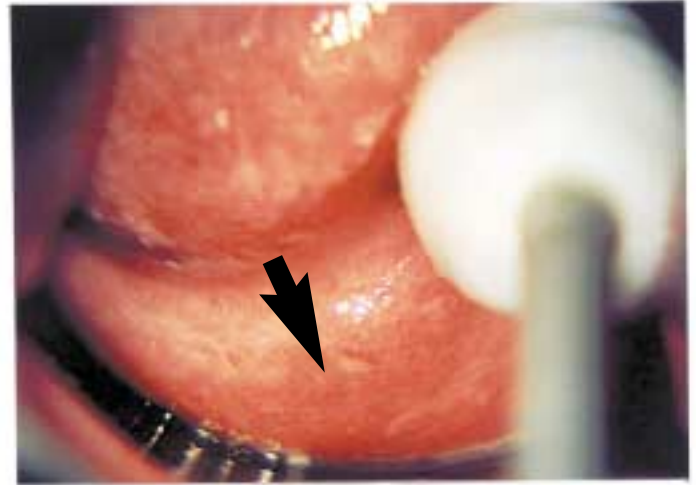
1. **PATIENT POSITIONING:**  
The subject should lie on a soft examination table in the lithotomy position with leg supports so as to enable the perineum and vulva to be inspected. At all times, the comfort and privacy of the woman should be ensured.
2. **COLPOSCOPIC EXAMINATION OF EXTERNAL GENITALIA:**  
Using appropriate magnification (usually 4-10X), examine the external genitalia. Record findings. (See Note A.)
3. **INSERTION OF SPECULUM:**  
Use a speculum with sufficiently long blades to permit adequate visualization of the vagina and cervix. If necessary, apply a small amount of the lubricant specified in the study protocol to the external blades. Gently insert and open the speculum so as to prevent trauma and enable the cervix and upper vagina to be seen clearly. (See Note B.)
4. **NAKED EYE EXAMINATION OF VISIBLE EPITHELIUM:**  
Naked eye inspection of visible epithelial surfaces should be performed without manipulation. Record findings. (See Note A.)
5. **WET PREPARATION:**  
If a wet preparation, pH, or microbiological tests are performed, the sample should be obtained after the speculum is placed and initial visual examination is made, but prior to lavage. The sample should be taken from the vaginal pool or lateral vaginal wall (or as directed by the protocol) away from any apparent abnormal areas. The area from which the wet preparation is taken should be excluded from the subsequent examination, or findings should be noted as "probably iatrogenic - wet preparation site."
6. **LAVAGE:**  
Using a small (3-4 cc) bulb syringe, lavage the cervix and vaginal walls with normal saline to remove mucus and cellular debris. Avoid contact between the tip of the syringe and the epithelium. The lateral fornices may be lavaged without manipulation by directing the stream into them. Aspirate the fluid with the tip of the syringe against the inner surface of the posterior blade of the speculum. Use dry swabs only to remove obscuring fluid from the posterior blade that cannot be removed by aspiration. Do not use dry swabs in any other manner and do not permit contact between the syringe or the dry swabs and the epithelium. Record any observations not noted on previous naked eye examination. (See Note C.)

## **PHOTOGRAPHIC EXAMPLES OF COLPOSCOPIC FINDINGS**

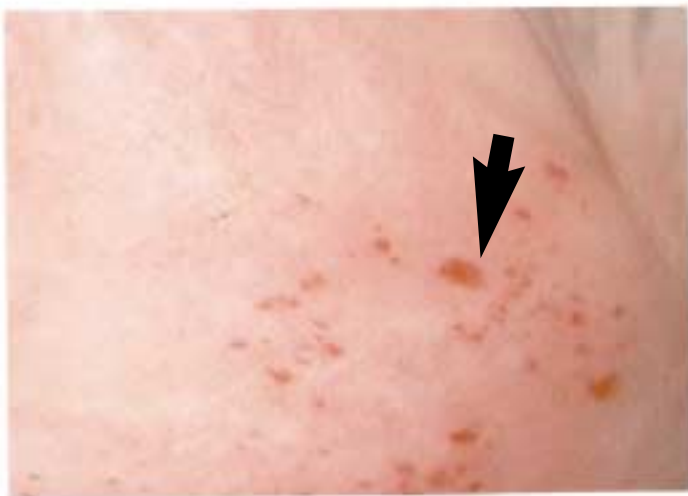These pages may be detached for display



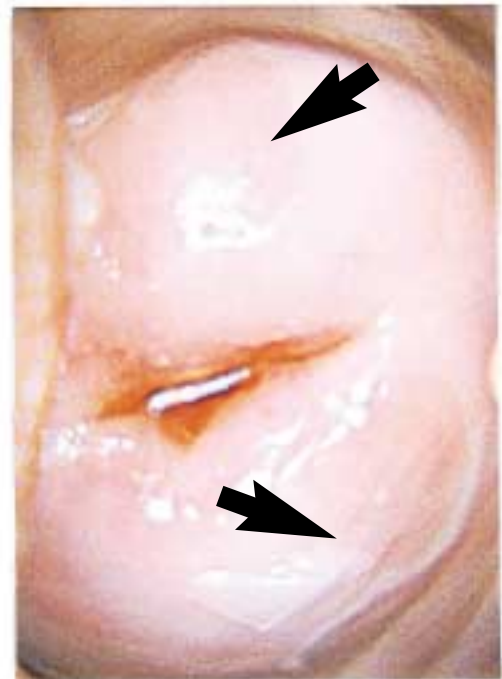#1: External genitalia:  
Epithelium intact/blood vessels intact,  
color red



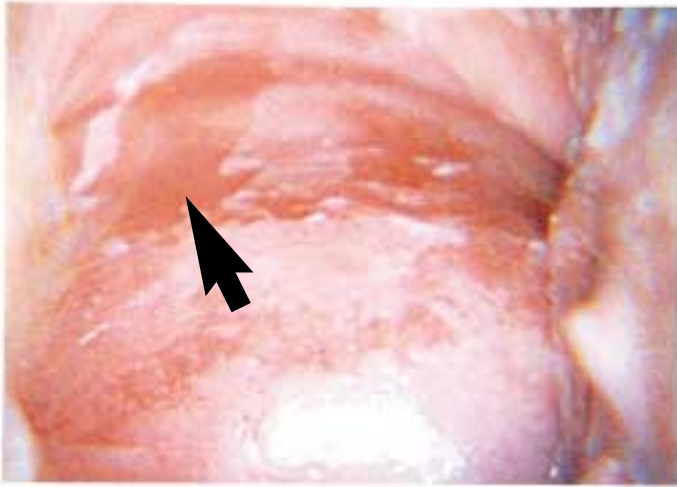
#2: Posterior cervical trunk and posterior fornix:  
Epithelium intact/blood vessels intact,  
color red



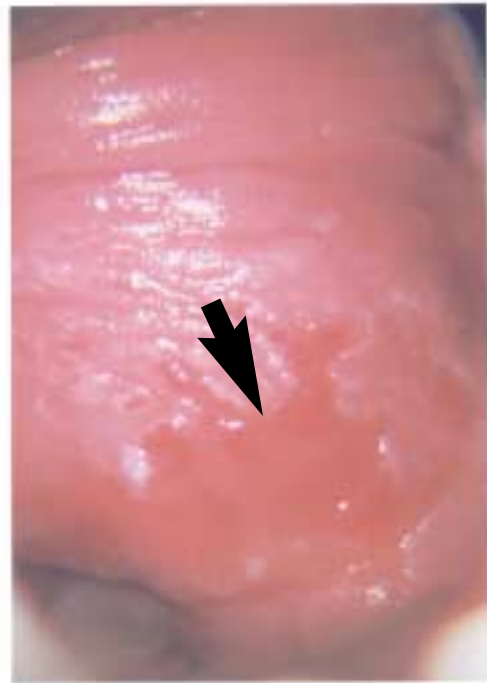#3: Right fornix and right cervical trunk:  
Epithelium intact/blood vessels disrupted,  
color red



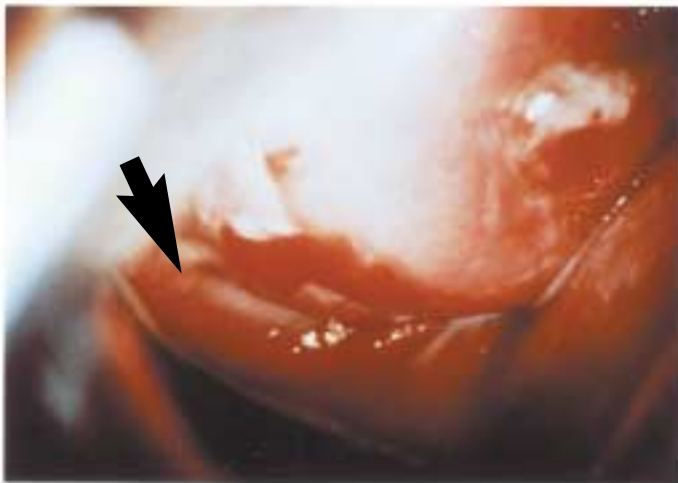
#4: Cervical face:  
Epithelium superficially disrupted/blood  
vessels intact, color normal



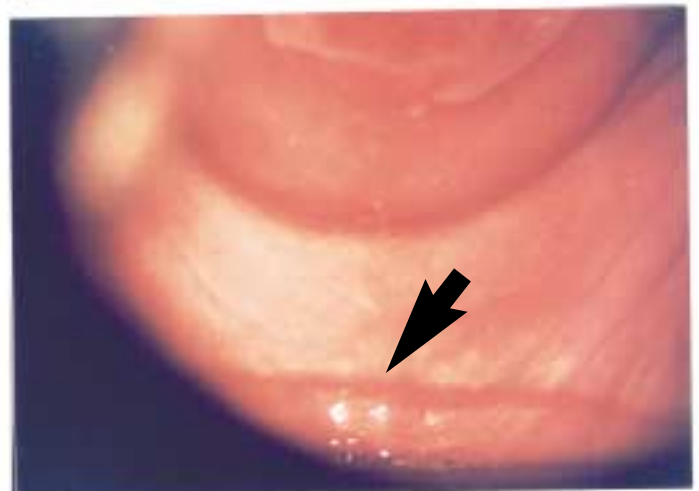#5: Anterior cervical trunk and anterior fornix:  
Epithelium superficially disrupted/blood vessels intact, color red



#6: Anterior cervical trunk and anterior fornix:  
Central finding: Epithelium superficially disrupted/blood vessels intact, color red  
Surrounding finding: Epithelium intact/blood vessels intact, color red



#7: Cervical face:  
Epithelium deeply disrupted/blood vessels not intact, color red



#8: Posterior fornix:  
Speculum trauma

#### Photographs:

- #1-6 and #8 provided by CONRAD investigators, Eastern Virginia Medical School, Norfolk, Virginia, USA
- #7 provided by Dr. Somchai Niruthisard, Chulalongkorn Hospital, Bangkok, Thailand



7. **COLPOSCOPIC EXAMINATION OF CERVIX:**  
Inspect the cervix under appropriate magnification (usually 4-10X) and record findings. (See Note A).
8. **COLPOSCOPIC EXAMINATION OF FORNICES:**  
Under appropriate magnification (usually 4-10X), examine the anterior, right lateral, left lateral, and posterior fornices and adjacent cervical trunk and record findings. If necessary, slightly manipulate speculum so that fornices may be adequately visualized. The lateral fornices are best exposed by placing a saline-moistened swab into the contralateral fornix and pressing toward the head and laterally. For example, to view the right lateral fornix, place the moistened swab into the left lateral fornix and press gently toward the woman's head and left side. A dry swab should never be used. (See Note D.)
9. **COLPOSCOPIC EXAMINATION OF VAGINA:**  
To examine the rest of the vagina, slowly withdraw the speculum with the blades moderately open, refocusing as needed. Record findings. (See Note A.)

NOTES:

A) Photography is not required but may be desirable for documentation, quality assurance, and/or independent blinded review of findings. Some means of standardizing assessment, such as by placement of a plastic disk of known diameter and color near the finding, should be used if possible. Baseline photography is especially helpful if subsequent examinations are separated by time or by multiple other examinations.

B) The length and axis of the vagina, position of the uterus, and least traumatizing type/size of speculum should be recorded on the source document during the first examination for reference at later examinations. This information should be reviewed prior to subsequent examinations to reduce the chance of causing iatrogenic injury.

C) Some protocols may require collection of lavage fluid for measurement of inflammatory markers. Note also that if the product obscures findings, it should be lavaged away as completely as possible using a medium specified in the protocol, and as much of the epithelial surface examined as possible.

D) At no time should a dry swab be used during examination of either the cervix or the vagina, as this may traumatize the epithelium of either surface. Large swabs moistened with non-bacteriostatic saline should be used.

## DESCRIPTION OF FINDINGS

The nomenclature to use for findings has been simplified. The results of the colposcopic examination should be documented by recording the following for each numbered finding:

### 1) Epithelium:

- Integrity:
  - Intact
  - Disrupted
    - Superficial
    - Deep: Complete disruption is now called “deep” and exposes stroma and possibly blood vessels. A bleeding area should be considered “deep”.
- Color: normal, slightly red, red, white, other (including pale)

### 2) Blood vessels:

- Integrity:
  - Intact
  - Disrupted

The terms in italics in Table 2 are from the original WHO procedure. They have been replaced with the descriptors in bold.

**TABLE 2**  
**DOCUMENTATION OF FINDINGS\***

	<b>Blood vessels intact</b>	<b>Blood vessels disrupted</b>
<b>Epithelium intact</b>	<i>Erythema (color red or slightly red)</i> <i>Edema (color pale)</i>	<i>Ecchymosis</i> <i>Petechiae</i> <i>Petechial hemorrhage</i>
<b>Epithelium disrupted – superficial</b>	<i>Abrasion</i> <i>Ulcer</i>	<i>Abrasion</i> <i>Ulcer</i>
<b>Epithelium disrupted – deep</b>	<i>Abrasion</i> <i>Ulcer</i>	<i>Abrasion</i> <i>Ulcer</i>

- Findings previously called “erythema” or “edema” should be described as an area with intact blood vessels and epithelium. Erythema should be distinguished from edema by the former having a red or slightly red color and the latter being pale.
  - Findings previously called “ecchymosis,” “petechiae,” and “petechial hemorrhage” should be described as an area with disrupted blood vessels and intact epithelium. (The size of these and all findings should continue to be recorded.)
  - Findings previously called “abrasion” or “ulcer” should be described as an area with either intact or disrupted blood vessels and superficially or deeply disrupted epithelium, as appropriate.
- \* Findings referred to as “peeling” or “deepithelialization” by some researchers should be recorded as an area with superficially disrupted epithelium and intact blood vessels.

## RECORD OF COLPOSCOPIC FINDINGS

1. Finding number .....    
(if previously reported, use same finding number)

2. Size of entire finding .....   
1: <5 mm                      2: 5-10 mm  
3: >10 mm

3. Epithelium/surface .....   
0=Intact (**go to Q.5**)      1=Not intact

4. If epithelium not intact, indicate depth.....   
1=Superficial                  2=Deep

5. Color of epithelium.....   
1=Normal                      2=Slightly red  
3=Red                            4=White  
5=Other --> specify: \_\_\_\_\_

6. Blood vessels .....   
0=Intact                      1=Not intact

7. Is any part of the finding located on the external genitalia .....   
0=No (**go to Q.9**)            1=Yes

8. For each of the following parts of the external genitalia, indicate if it is involved in the finding.  
0=No, and 1=Yes.  
If YES, indicate percent of area involved in the finding\*.

INVOLVED    % OF AREA

a) Right Labia Majora .....	<input type="checkbox"/>	<input type="checkbox"/>	<input type="checkbox"/>
b) Left Labia Majora .....	<input type="checkbox"/>	<input type="checkbox"/>	<input type="checkbox"/>
c) Right Labia Minora .....	<input type="checkbox"/>	<input type="checkbox"/>	<input type="checkbox"/>
d) Left Labia Minora .....	<input type="checkbox"/>	<input type="checkbox"/>	<input type="checkbox"/>
e) Clitoris/prepuce .....	<input type="checkbox"/>	<input type="checkbox"/>	<input type="checkbox"/>
f) Vestibule .....	<input type="checkbox"/>	<input type="checkbox"/>	<input type="checkbox"/>
g) Perineum .....	<input type="checkbox"/>	<input type="checkbox"/>	<input type="checkbox"/>
h) Other --> .....	<input type="checkbox"/>	<input type="checkbox"/>	<input type="checkbox"/>

specify: \_\_\_\_\_

9. Is any part of the finding located on the cervix.....   
0=No (**go to Q.11**)            1=Yes

10. For each of the following parts of the cervix, indicate if it is involved in the finding.  
0=No, and 1=Yes.  
If YES, indicate percent of area involved in the finding\*.

INVOLVED    % OF AREA

a) Anterior cervical trunk .....	<input type="checkbox"/>	<input type="checkbox"/>	<input type="checkbox"/>
b) Posterior cervical trunk .....	<input type="checkbox"/>	<input type="checkbox"/>	<input type="checkbox"/>
c) Right lateral cervical trunk.....	<input type="checkbox"/>	<input type="checkbox"/>	<input type="checkbox"/>
d) Left lateral cervical trunk .....	<input type="checkbox"/>	<input type="checkbox"/>	<input type="checkbox"/>
e) Cervical face .....	<input type="checkbox"/>	<input type="checkbox"/>	<input type="checkbox"/>

11. Is any part of the finding located in the vaginal fornix .....   
0=No (**go to Q.13**)            1=Yes

12. For each of the following parts of the vaginal fornix, indicate if it is involved in the finding.  
0=No, and 1=Yes.  
If YES, indicate percent of area involved in the finding\*.

INVOLVED    % OF AREA

a) Anterior .....	<input type="checkbox"/>	<input type="checkbox"/>	<input type="checkbox"/>
b) Posterior .....	<input type="checkbox"/>	<input type="checkbox"/>	<input type="checkbox"/>
c) Right lateral .....	<input type="checkbox"/>	<input type="checkbox"/>	<input type="checkbox"/>
d) Left lateral .....	<input type="checkbox"/>	<input type="checkbox"/>	<input type="checkbox"/>

13. Is any part of the finding located on the vaginal wall .....   
0=No (**end here**)            1=Yes

14. For each of the following parts of the vaginal wall, indicate if it is involved in the finding.  
0=No, and 1=Yes.  
If YES, indicate percent of area involved in the finding\*.

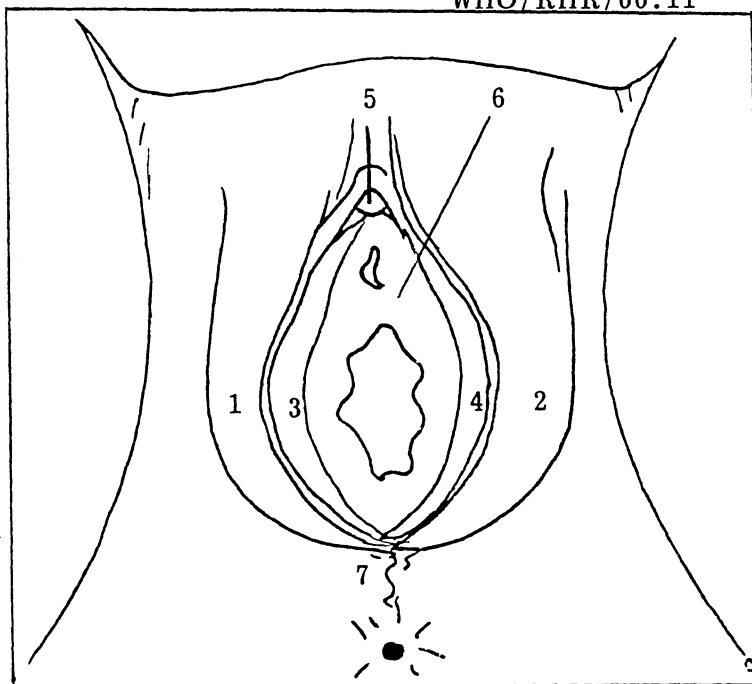
INVOLVED    % OF AREA

a) Anterior, proximal half.....	<input type="checkbox"/>	<input type="checkbox"/>	<input type="checkbox"/>
b) Anterior, distal half .....	<input type="checkbox"/>	<input type="checkbox"/>	<input type="checkbox"/>
c) Posterior, proximal half.....	<input type="checkbox"/>	<input type="checkbox"/>	<input type="checkbox"/>
d) Posterior, distal half .....	<input type="checkbox"/>	<input type="checkbox"/>	<input type="checkbox"/>
e) RT lateral, proximal half ....	<input type="checkbox"/>	<input type="checkbox"/>	<input type="checkbox"/>
f) RT lateral, distal half .....	<input type="checkbox"/>	<input type="checkbox"/>	<input type="checkbox"/>
g) LFT lateral, proximal half....	<input type="checkbox"/>	<input type="checkbox"/>	<input type="checkbox"/>
h) LFT lateral, distal half .....	<input type="checkbox"/>	<input type="checkbox"/>	<input type="checkbox"/>

**\*PERCENT CODES:**

1= 1% to 25%	2= 26% to 50%
3= 51% to 75%	4= greater than 75%

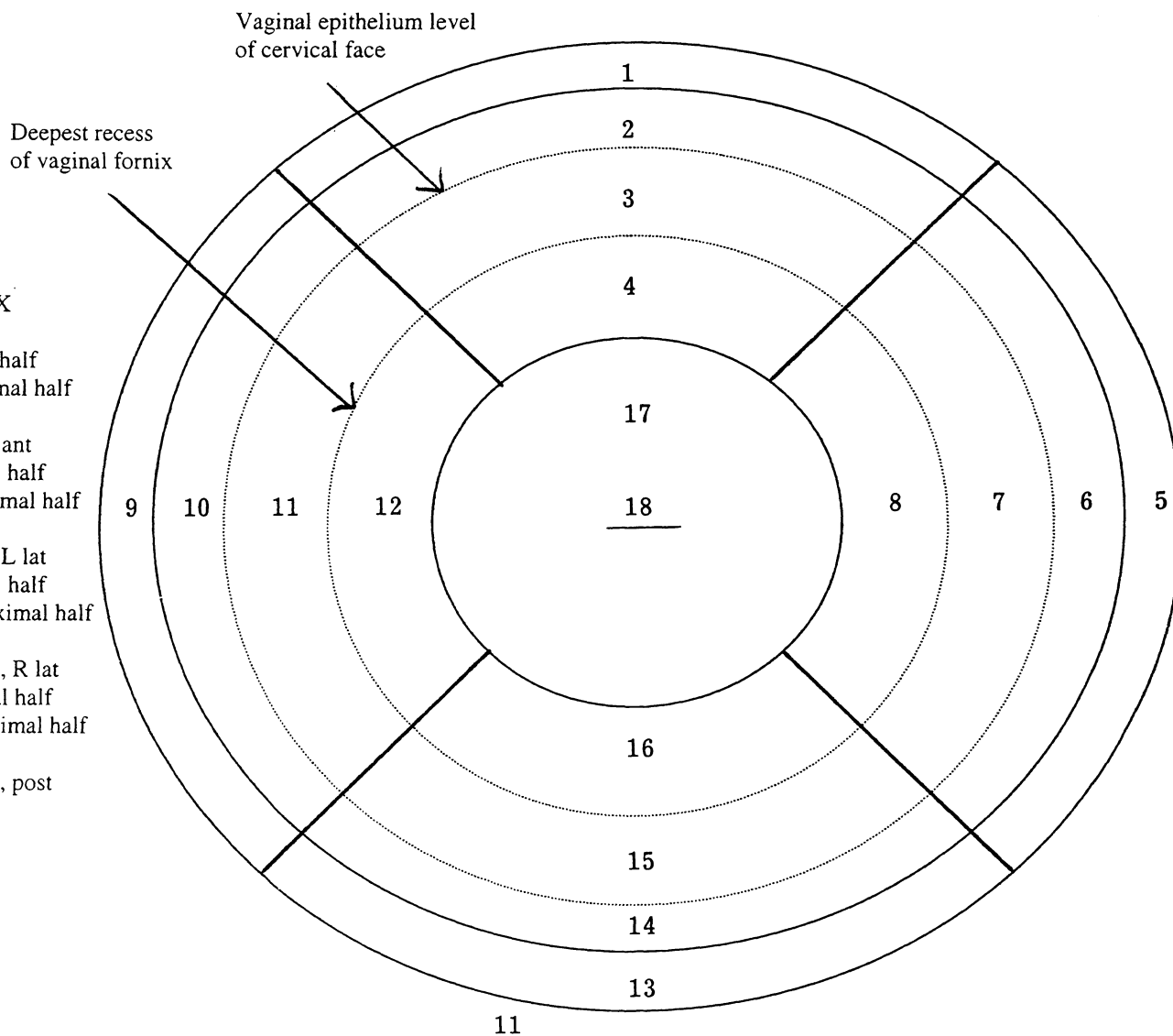
## EXTERNAL GENITALIA



### LEGEND FOR EXTERNAL GENITALIA

- 1 - R lab maj
- 2 - L lab maj
- 3 - R lab min
- 4 - L lab min
- 5 - Clitoris/prepuce
- 6 - Vestibule
- 7 - Perineum
- 8 - Other \_\_\_\_\_

## VAGINA AND CERVIX



### LEGEND FOR VAGINA/CERVIX

- 1 - Ant vag, distal half
- 2 - Ant vag, proximal half
- 3 - Ant fornix
- 4 - Cervical trunk, ant
- 5 - L lat vag, distal half
- 6 - L lat vag, proximal half
- 7 - L lat fornix
- 8 - Cervical trunk, L lat
- 9 - R lat vag, distal half
- 10 - R lat vag, proximal half
- 11 - R lat fornix
- 12 - Cervical trunk, R lat
- 13 - Post vag, distal half
- 14 - Post vag, proximal half
- 15 - Post fornix
- 16 - Cervical trunk, post
- 17 - Cervical face
- 18 - Os

## BIBLIOGRAPHY

### Colposcopy in sexually active women not using any product

Mauck CK, Baker JM, Birnkrant DB, Rowe PJ, Gabelnick HL. The use of colposcopy in assessing vaginal irritation in research: report from a conference. *AIDS* 2000; 14: (in press).

Van de Wijgert J, Chirenje Z, Iliff V, Coggins C, Winikoff B, Padian N. The role of colposcopy in evaluating vaginal products. Abstracts from the Microbicides 2000 Meeting 2000; 48.

Fraser IS, Lahteenmaki P, Elomaa K, et al. Variations in vaginal epithelial surface appearance determined by colposcopic inspection in healthy, sexually-active women. *Human Reprod* 1999; 14: 1974-1978.

Norvell MK, Benrubi GI, Thompson RJ. Investigation of microtrauma after sexual intercourse. *J Repro Med* 1984; 29: 269-71.

### Colposcopy in women using tampons

Raudrant D, Landrison G, Frappart L, De Haas P, Champion F, Ecochard R. Comparison of the effects of different menstrual tampons on the vaginal epithelium: a randomised clinical trial. *Eur J Obstet Gynecol Repro Bio* 1995; 58: 41-46.

Raudrant D, Frappart L, De Haas P, Thoulon JM, Charvet F. Study of the vaginal mucous membrane following tampon utilisation; aspect on colposcopy, scanning electron microscopy and transmission electron microscopy. *Eur J Obstet Gynecol Repro Bio* 1989; 31: 53-65.

Berkeley AS, Micha JP, Freedman KS, Hirsch JC. The potential of digitally inserted tampons to induce vaginal lesions. *Obstet Gynecol* 1985; 66: 31-5.

Friedrich EG, Siegesmund KA. Tampon-associated vaginal ulcerations. *Obstet Gynecol* 1980; 55: 149-56.

### Colposcopy in women using female condoms

Soper DE, Brockwell NJ, Dalton HP. Evaluation of the effects of a female condom on the female lower genital tract. *Contraception* 1991; 44: 21-29.

### Colposcopy in vaginal ring studies

Fraser I, Lacarra M, Mishell D, Alvarez F, Brache V, Lahteenmaki P, Elomaa K, Weisberg E, Nash H. Vaginal epithelial surface appearances in women using vaginal rings for contraception.

Contraception 2000; 61:131-138.

United Nations Development Programme/United Nations Population Fund/World Health Organization/World Bank, Special Programme of Research, Development and Research Training in Human Reproduction. A randomised comparison of the effects on vaginal and cervical epithelium of a placebo vaginal ring with non-use of a ring. Contraception 2000; 62: (in press).

Bounds W, Szarewski A, Lowe D, Guillebaud J. Preliminary report of unexpected local reactions to a progestogen-releasing contraceptive vaginal ring. Eur J Obstet Gynecol Repro Bio 1993; 48: 123-25.

Colposcopy in N-9 studies

Van Damme L, Chandeying V, Ramjee G, Rees H, Sirivongrangson P, Laga M, Perriens J. Safety of multiple daily applications of COL-1492, a nonoxynol-9 vaginal gel, among female sex workers. AIDS 2000 ; 14: 85-88.

Stafford MK, Ward H, Flanagan A, Rosenstein IJ, Taylor-Robinson D, Smith JR, Weber J, Kitchen VS. Safety study of nonoxynol-9 as a vaginal microbicide: evidence of adverse effects. J AIDS 1998; 17: 327-31.

Martin HL, Stevens CE, Richardson BA, Rugamba D, Nyange PM, Mandaliya K, Ndinya-Achola J, Kreiss JK. Safety of a nonoxynol-9 vaginal gel in Kenyan prostitutes. Sex Tran Dis 1997; 24: 279-283.

Mauck CK, Baker JM, Barr SP, Johanson WM, Archer DF. A phase I comparative study of three contraceptive vaginal films containing nonoxynol-9 (Postcoital testing and colposcopy). Contraception 1997; 56: 97-102.

Poindexter AN, Levine H, Sangi-Haghpeykar H, Frank ML, Grear A, Reeves KO. Comparison of spermicides on vulvar, vaginal, and cervical mucosa. Contraception 1996; 53: 147-53.

Ward H, Stafford M, Flanagan A, et al. Phase one study of the safety and tolerability of nonoxynol-9: histological evidence of an inflammatory response. Abstract: Presented at the XI International Conference on AIDS, 1996.

Roddy RE, Cordero M, Cordero C, Fortney JA. A dosing study of nonoxynol-9 and genital irritation. Int J of STD AIDS 1993; 4: 165-70.

Niruthisard S, Roddy RE, Chutivongse S. The effects of frequent nonoxynol-9 use on the vaginal and cervical mucosa. STD 1991; 18: 176-79.

Colposcopy in menfegol studies

Goeman J, Ndoye I, Sakho LM, Mboup S, Piot P, Karam M, Belsey E, Lange JMA, Laga M, Perriens J. Frequent use of menfegol spermicidal vaginal foaming tablets associated with a high incidence of genital lesions. *J Inf Disease* 1995; 171: 1611-4.

Colposcopy in dextrin sulfate studies

Low-Beer Naomi, Sunders A, Nunn A, McCormack S, Kitchen V, Lacy C. Dextrin sulfate vaginal gel: interim data from a phase II study in sexually active healthy women at low risk of HIV infection and their male partners. Abstracts from the Microbicides 2000 Meeting 2000; 41.

Stafford MK, Cain D, Rosenstein I, Fontaine EA, McClure M, Flanagan AM, Smith JR, Taylor-Robinson D, Weber J, Kitchen VS. A placebo-controlled, double-blind prospective study in healthy female volunteers of dextrin sulphate gel. *J AIDS* 1997; 14: 213-8.

Colposcopy in benzalkonium chloride studies

Mauck CK, Baker JM, Barr SP, Abercrombie TJ, Archer DF. A phase I comparative study of contraceptive vaginal films containing benzalkonium chloride and nonoxynol-9 (Postcoital testing and colposcopy). *Contraception* 1997; 56: 89-96.

Colposcopy in PRO 2000 studies

Profy A, Sonderfan A, Chancellor T, McKinlay M. PRO 2000 Gel: a candidate topical microbicide based on a naphthalene sulfonate polymer with antimicrobial and contraceptive properties. Abstracts from the Microbicides 2000 Meeting 2000; 44.

Van Damme L, Wright A, Depraetere K, Rosenstein I, Vandersmissen V, Poulter L, McKinlay M, Van Dyck E, Weber J, Profy A, Laga M, Kitchen V. A phase I study of a novel potential intravaginal microbicide, PRO 2000, in healthy sexually inactive women. *Sex Transm Infect.* 2000 Apr; 76(2): 126-30.

Wright A, Rosenstein I, Poulter L, et al. Safety and tolerability of PRO 2000 gel: a potential vaginal virucide. Abstract: Presented at the 5<sup>th</sup> Congress on Retroviruses and Opportunistic Infections, 1998.

Colposcopy in BufferGel studies

Van de Wijgert J, Nelson K, Fullem A, Kumwenda N, Mehendale S, Rugpao S, Joglekar N, Taha T, Bollinger R, Padian N, Heagerty P, Kelly C, Rosenberg Z. Safety results of a multi-site international phase I trial of the topical microbicide Buffergel. Abstracts from the Microbicides 2000 Meeting 2000; 47.

Mayer K. BufferGel: results of the of the first phase I study of a novel vaginal microbicide. Abstract: Presented at 12<sup>th</sup> World AIDS Conference, 1998.

Colposcopy in Polycresulen studies

Kilmarx PH, Limpakarnjanarat K, Supawitkul S, Korattana S, Young NL, Parekh BS, Respass RA, Mastro TD, St. Louis ME. Mucosal disruption due to use of a widely-distributed commercial vaginal product: potential to facilitate HIV transmission, AIDS 1998; 12: 767-773.

Colposcopy in carrageenan studies

Elias CJ, Coggins C, Alvarez F, Brache V, Fraser IS, Lacarra M, et al. Colposcopic evaluation of a vaginal gel formulation of iota-carrageenan. Contraception 1997; 56: 387-9.

Colposcopy in Acidform Studies

Amaral E, Faundes A, Waller D, Garg S, Zaneveld L. Study of the vaginal tolerance to ACIDFORM, an acid-buffering, bio-adhesive gel with nonoxynol-9. Abstracts from the Microbicides 2000 Meeting 2000; 35.

Colposcopy with digital video imaging

Craine BL, Craine ER. Digital imaging colposcopy: basic concepts and applications. Obstet Gynecol 1993; 82: 869-73.

Crisp WE, Craine BL, Craine EA. The computerized digital imaging colposcope: future directions. Am J Obstet Gynecol 1990; 162: 1491-8.

Alternative markers for inflammation

Fichorova RN, Anderson DJ. Cytokines in the cervical vaginal environment. In: Hill J, ed. Cytokines in Human Reproduction. Georgetown, TX: Landes Bioscience, 1999 (in press).

Fichorova RN, Anderson DJ. Differential expression of immunobiological mediators by immortalized human cervical and vaginal epithelial cells. Bio of Reprod 1999; 60: 508-514.

Fichorova RN, Rheinwald JG, Anderson DJ. Generation of papillomavirus-immortalized cell lines from normal human ectocervical, endocervical, and vaginal epithelium that maintain expression of tissue-specific differentiation proteins. Bio of Reprod 1997; 57: 847-55.

Anderson DJ, Politch JA, Tucker LD, Fichorova RN, Haimovici F, Tuomala RE, Mayer KH. Quantitation of mediators of inflammation and immunity in genital tract secretions and their relevance to HIV type 1 transmission. AIDS Research and Human Retroviruses 1998; 14: 43-9.





