

WHO/BILH/67.61

ORIGINAL: FRENCH

DETERMINATION OF A LIMITED FOCUS OF ARTERIOVENOUS BILHARZIASIS
IN THE PROVINCE OF SITHADONE (SOUTH LAOS)

by

M. Barbier
Département de Parasitologie et Pathologie exotique
Hôpital International de l'Université de Paris
Paris, XIV, France



CONTENTS

	<u>Page</u>
1. Introduction	2
2. Cases	2
3. Comments	7
3.1 Clinical characteristics	7
3.2 Morphological characteristics of the eggs	8
3.3 Epidemiological characteristics.	8
4. Conclusions.	10
Acknowledgements	10
References	11

The issue of this document does not constitute formal publication. It should not be reviewed, abstracted or quoted without the agreement of the World Health Organization. Authors alone are responsible for views expressed in signed articles.

Ce document ne constitue pas une publication. Il ne doit faire l'objet d'aucun compte rendu ou résumé ni d'aucune citation sans l'autorisation de l'Organisation Mondiale de la Santé. Les opinions exprimées dans les articles signés n'engagent que leurs auteurs.

1. INTRODUCTION

The geographical distribution in south-east Asia of arteriovenous bilharziasis caused by Schistosoma japonicum is rightly a matter of concern both to the health authorities of the countries in that area and to the World Health Organization.

A few sporadic cases of this disease have, in fact, been reported since the last war, outside previously known foci in Japan, China, Formosa, the Philippines and Celebes, especially in Thailand (Chaiyaporn, Koonvisal & Dharamadhach, 1959; Harinasuta & Kruatrachue, 1962; Lee, Wykoff & Beaver, 1966).

The purpose of this paper is to draw attention to five cases of arteriovenous bilharziasis observed in Laotian students studying in Paris and followed up in the parasitology department of the International Hospital, University of Paris, since 1964.

2. CASES

Case No. 1. The first case concerns an attaché of the Embassy of Laos in Peking. He was admitted to the Parasitology Department because of epileptic attacks, unaccompanied by electroencephalographic changes, which occurred for the first time in August 1963 when he was 23 years of age and living in London.

He was born in Vientiane, but there is no precise information on any stays he may have made in the south of Laos. It is also known that at 16 years of age he suffered from a general dysenteric syndrome with several relapses treated by means of indigenous remedies. Until 18 years of age, he suffered from sub-acute colitic troubles which seem to have disappeared spontaneously later on. During his stay in Peking, the hotel conditions were excellent and he practically never left the city.

Clinically speaking, there was no change in regard to digestion. Biologically, the only abnormality was an eosinophil rate of 14 per cent.

Liver function tests were more or less normal.

Stool examination revealed the presence of: Iodamoeba bütschlii, Tricharis Clonorchis sinensis and Schistosoma japonicum.

Rectoscopy showed no inflamed or hyperplastic conditions of the mucosa, but the biopsy sample examined using the chloral gum technique revealed the presence of numerous egg inclusions.

In the case of this patient, the geographical inquiry was unfortunately not sufficiently thorough. Although the author was aware of the absence of known foci of bilharziasis in Laos, sufficient attention was not paid to this isolated case, perhaps because of the trips made to China.

The same does not apply to the following cases, which, because of their repetitive nature, led the author to make the fullest possible epidemiological and geographical investigations.

Case No. 2. The second patient was a 25 year old South Laotian who had been studying in the School of Public Works in France for six months. He was born at Hat Sai (Province of Sithadone) a village on the east bank of the Mekong, facing the island of Khong.

He came for consultation because of symptoms of colitis, persistent headache without neurological or migraine symptoms, and marked asthenia.

Interrogation revealed that he had attended the primary school in Khong. He had frequently gone fishing for carp, frogs or even snails in the rice fields around the town. Following these excursions, he had often experienced an unpleasant itching between the toes persisting for several hours; this was also noted by his companions on such expeditions.

The case history showed that apart from attacks of malaria, there had been acute colitic disorders with rectal haemorrhage taking on a paroxysmal nature at the age of 18. When he was 21 years old, a new dysenteric episode was attributed to amoebiasis and treated as such.

The clinical findings were left colitis and mild splenomegaly without hepatomegaly. The eosinophil rate was six per cent. Liver function flocculation tests showed little change.

ESP clearance tests showed a deficiency within the range of cirrhogenous chronic hepatitis. In the stools were found Clonorchis sinensis, Necator americanus and a few rare eggs of Schistosoma japonicum. Rectoscopy revealed congestive and hyperplastic rectosigmoiditis with inflammatory valvulitis but without any distinct loss of outline. A biopsy sample examined by the chloral gum technique showed numerous egg inclusions. The Vogel & Minning cercarial envelope reaction (CHR) was positive (+++).

Case No. 3. The third patient was a science student, aged 20, who had been in France for a year. He was born in the village of Moun Sène on the west coast of Khong island. He too had attended the Khong primary school and taken part in fishing excursions in the rice fields. Like the previous case, he mentioned itching between the toes.

During adolescence, there had been a few rare episodes of rectal haemorrhage and signs of colitis with alternating diarrhoea and constipation.

Clinically, moderate splenomegaly was noted, without enlargement of the liver. Neurological signs were absent.

Biological investigation revealed an eosinophil rate of nine per cent. and disturbed liver function flocculation tests (Manger positive, Kunkel zinc 65 U, RCT +++, Maclagan 20 UV). The liver clearance tests, and particularly the two-slope ESP test, showed a distinct deficit, and a corresponding graph, lying within the cirrhogenous hepatitis range, and a distinct deficiency in the Quick test (induced hippuria).

In the stools, Schistosoma japonicum was detected. Rectoscopic examination showed the valves to be hyperplastic but little inflamed; a biopsy sample examined by the chloral gum technique showed egg inclusions. Laparoscopy revealed an enlarged liver, particularly the left lobe which appeared very congested but without any visible nodule. Perihepatitis was noted, taking the form of small white plaques sometimes with an aphthoid aspect. Pathological examination of the liver biopsy (carried out by Dr F. Martin) showed the trabecular structure and the liver cells to be intact. Near the portal spaces, mild sclerosis was noted, with thickening of the collagen bundles in contact with a lymphoplasmocytic inflammatory

infiltration. In one of the sections a small fibrohyalin nodule was found in a portal space, but without any trace of clearly identifiable parasitic bodies.

This, therefore, was a case of portal sclerosis with mild inflammatory lesion unaccompanied by cirrhosis.

Examination of the same liver biopsy by the chloral gum technique revealed the presence of clearly identifiable egg inclusions although the miracidia had degenerated.

Case No. 4. The fourth case was discovered in March 1965 by Dr Jardin of Rennes, whom the patient had consulted for rectal haemorrhage. Rectal biopsy was performed at the site of the hyperplastic lesions and revealed inclusions of Schistosoma japonicum eggs. The result had been confirmed by stool examinations made at the Faculty of Pharmacy, Rennes. A liver biopsy, studied in the pathological anatomy laboratory of Rennes Hospital, showed the trabecular structure to be intact. On the other hand, in one of the portal spaces dense and extensive fibrosis was noted, which was hyalinized with an inflammatory infiltrate comprising an association of lymphohistiocytes with some polynuclear cells. In addition, a slight dilatation of the sinusoids was noted, as well as swelling of the Kupffer cells, without pigmentary granulation.

After a course of anthiomaline treatment, the patient still continued to suffer from marked colitic upsets which seemed to worsen considerably in November 1965. He was seen by the author at that time and it was decided, in agreement with Professor Brumpt, to administer nitrothiazole treatment.

Epidemiological and geographical inquiry revealed that the patient was born at Boun Toi, a village situated on the east bank of the Mekong, between Phiafay and Khong island. When he was two years of age, his family went to live at Phiafay. During this period, he suffered fairly frequently from attacks of malaria. When he was five years old, he went to Khong, where he lived until 14 years of age. He attended the Khong primary school and took part in fishing excursions. At eight years of age, he noted occasional rectal haemorrhages which reoccurred over a period of two years. He told his parents, but these symptoms seem to be so frequent among children in this area that they did not attach much importance to them.

Clinically, we did not find any definite enlargement of the liver or spleen; the eosinophil rate was two per cent. The liver function flocculation tests revealed a moderate degree of disturbance, as did also the clearance tests.

Rectoscopy showed several bilharziomas to be present, as well as a typical deformation of Houston's valve, with loss of the concave outline. The Vogel & Minning test was positive (+++) and immunological analysis (immunodiffusion and immunoelectrophoresis carried out by Professor Capron in Lille with Schistosoma japonicum antigens) showed a precipitation curve insoluble in sodium citrate.

Case No. 5. The fifth patient was a senior official on a study trip to France. He was born on 20 April 1930 in Veunthong, a village in the north of Khong island.

It was during a test for taeniasis that this patient was found to be suffering from Schistosoma japonicum bilharziasis, apparently asymptomatic. The case history included probable attacks of malaria. The patient had attended the Khong primary school and frequently participated in fishing excursions, either in the Mekong or in the rice fields surrounding Khong, with itching between the toes on his return. At that time, there had been some attacks of rectal haemorrhage. Clinically, there was no enlargement of the spleen or liver and the neurological examination was normal.

The eosinophil rate was 18 per cent., but there had been recent taeniasis. The flocculation and clearance tests for liver function were normal apart from a positive Hanger test (++) .

Stool examination revealed the presence of numerous Charcot-Leyden crystals and numerous Clonorchis sinensis eggs. No hyperplastic lesions were found on carrying out a rectoscopy. Study of a rectal biopsy using the chloral gum technique showed the presence of egg inclusions; a liver biopsy, examined by the same technique, revealed the presence of a fairly large number of egg inclusions (47 were counted in the section studied); pathological examination of the liver biopsy (carried out by Dr F. Martin) showed the trabeculae and the liver cells to be intact. There was solely a certain stenosis of the portal spaces with, here and there, slight lipochromic pigmentary infiltration without inflammatory infiltration or nodule formation.

3. COMMENTS

3.1 Clinical characteristics

Consideration of the clinical aspects of these cases is not the aim of this paper. However, it seems justifiable to stress their main characteristics.

- (a) Colitic manifestations at this stage of the disease are far from being constant and their absence should not lead to a rejection of the diagnosis.
- (b) Clinical changes in the liver and spleen were very slight in these cases, although in three of them there were distinct peri-portal histological lesions of the liver.
- (c) The possibility of cerebral involvement cannot be neglected.
- (d) There should be no illusions regarding the results of stool examination, although here they were positive in three cases out of five. Diagnosis is difficult to establish by this method, particularly during systematic routine examinations. The eggs are very rare. The successful results reported were only obtained by repeated specific concentrations calling for long hours of laboratory work. (In general, the author prefers the Ritchie concentration technique to the merthiolate one, which does not seem to give better results.)
- (e) The results of rectal biopsy were positive in all cases, this being due to the large number of eggs deposited and their extensive distribution in the rectosigmoid mucosa. Rectal biopsy of the rectal mucosa is thus the method of choice for establishing a parasitological diagnosis.
- (f) Examination of liver biopsies, using the chloral gum technique, led to the finding of a fairly large number of egg inclusions in two cases. It is interesting to compare this result with that of pathological examination, in which no egg inclusions were found. The two techniques should therefore be complementary in order to determine both the etiology and the lesions in hepatic bilharziasis.
- (g) The action of nitrothiazole treatment on the hepatic and colic lesions as well as on oviposition and the immunological reactions will be dealt with in another paper.

3.2 Morphological characteristics of the eggs

The adult worms and the larvae were not studied. Two of the strains were sent to the service directed by Professor Brumpt at the Institute of Parasitology, where Miss Therizol and Mr Picot succeeded in hatching out the eggs. However, the exposure of Oncomelania hupensis (specimens supplied by Professor Vogel of Hamburg) was not followed by the infection of this intermediate host.

The eggs obtained by stool examination, particularly from two of our patients, were sufficient for the average dimensions of a fairly large number of specimens to be calculated. We took the same precautions as Hsu & Hsu (1958); elimination of all eggs not lying in a plane parallel to their major axis, measurement based on the shell itself, neglecting the periovular agglomerate. Under these conditions, the average dimensions of the eggs were as follows:

Average length 61μ ; average width 50.8μ ; the "size index" was therefore 83.2 ($\frac{\text{width}}{\text{length}} \times 100$).

This index is shown in comparison with those determined for known strains of Schistosoma japonicum in the following table:

Laos	Thailand	Japan	Formosa	Philippines	China
83.2	83	76.3	71	69.6	68

There can be no doubt that this comparison reveals a striking morphological similarity to the strain studied by Kruatrachue & Harinasuta in Thailand.

On the contrary, there is a significant difference from the Chinese, Philippine and Formosan strains.

3.3 Epidemiological characteristics

In four of the cases reported the case history made it possible to fix the age when the primary infection occurred fairly accurately between six and 10 years, i.e. at the commencement of school age and at a time when the child becomes sufficiently independent to undertake, either alone or with others, excursions for games or fishing outside the village.

A fact of great importance is that this agreement as regards age is accompanied, in four of these cases, by a close agreement as regards place, as shown by the following table:

Case	Born at	Primary School	Probable primary infection
No. 2	Hat Sai Khonne	Khong	Fishing in rice-fields around Khong
No. 3	Moun Sène	"	"
No. 4	Boun Toi	"	"
No. 5	Veunthong	"	"

This agreement is strengthened by a fifth case: that kindly communicated to the author by Professor Vic-Dupont concerning a Laotian patient whose spleen was removed in 1957. This patient came from Khong island and it may be supposed that he attended the Khong primary school. As far as is known, this is the first reported observation of Katayama disease in a Laotian.

Finally, on 5 July Dr Ansari of WHO, who had been informed of these findings, told the author that Dr H. Most¹ had examined two patients suffering from arterio-venous bilharziasis, who might have contracted the infection either:

- (1) as a result of bathing in the Mekong at Khong, where they had spent several months in 1964-1965;
- (2) or in the Namsane and one of its small tributaries near Borikhane in 1965-1966;
- (3) or at Vientiane, where the baths are fed by river water.

The present author feels that the first of these hypotheses is no doubt the correct one. Systematic examination of Laotian and Cambodian students who have not lived in Khong has in fact never revealed the presence of bilharziasis, although so far 48 such subjects have been seen.

¹ Department of Preventive Medicine, New York University School of Medicine, New York, United States of America.

4. CONCLUSIONS

The facts as a whole set out above make it practically certain that there is a focus of endemic bilharziasis in Southern Laos, more precisely, in the island of Khong.

Why has this focus not been reported by the WHO mission? No doubt because of the unfortunate chance that one of the few parts of the Mekong basin not explored by the mission was precisely the Laos/Cambodia frontier region and the Khong area (see attached map).

Is the strain involved a Japanese one imported during the last war which has become adapted to local ecological conditions and to a new intermediate host?

The fact that this focus has gone unrecognized until recent years seems to support this theory. On the other hand, the morphological appearance of the eggs is against it, and it is more logical to consider this morphology, the absence of Oncomelania or known intermediate hosts and the absence of animal infection as being the specific characteristics of a sub-species or variety whose present geographical area of distribution is represented by the isolated foci found in South Laos and Thailand.

These conclusions have been reported to the World Health Organization which is still keenly interested in the geographical distribution, epidemiology and treatment of bilharziasis. It is not for the author to recommend the practical decisions that might be taken following this communication. However, it is to be hoped that they will aim at solving some of the problems raised in this paper, whether theoretical, (identification and origin of the Schistosoma, identification of the intermediate host), or practical (case finding and treatment of infected subjects, epidemiological control measures).

ACKNOWLEDGEMENTS


The author would like to thank in particular Professors Galliard and Brumpt with whom he discussed at length this problem with which they are so familiar.

He also thanks the team at the Institute of Parasitology, Faculty of Medicine of Paris, in particular Miss Ho Thi Sang, Messrs Petithory and Picot and Miss Therizole, for their technical assistance.

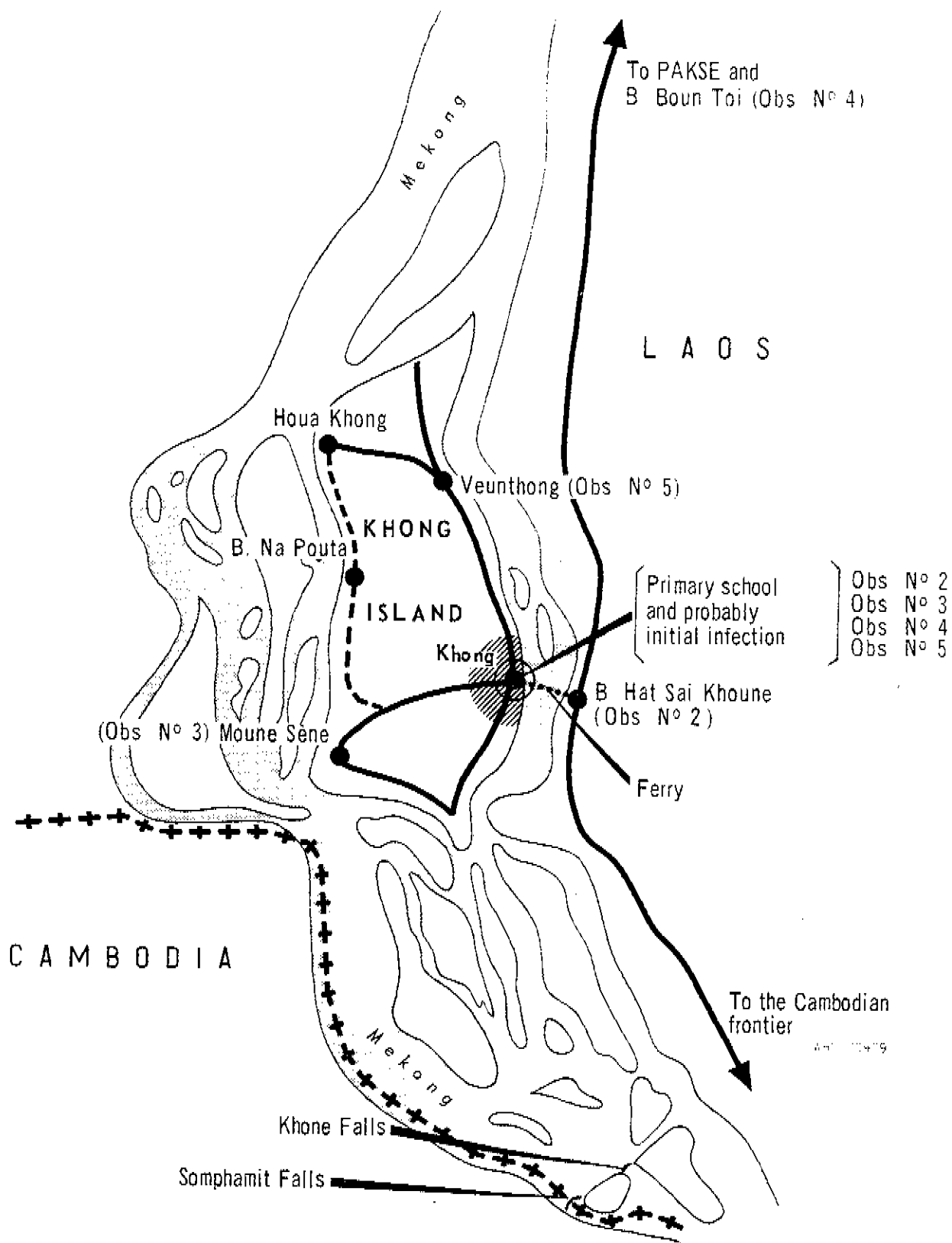
Finally, the author expresses his gratitude to Dr Lacourbe, Medical Superintendent of the International Hospital, University of Paris, for his kind assistance and for entrusting to him the Department of Exotic and Parasitic Pathology.

REFERENCES

- Chaiyaporn, V., Koonvisal, L. & Dharamadhach (1959) The first case of Schistosomiasis japonicum in Thailand, J. med. Ass. Thailand, 42, 438
- Harinasuta, C. & Kruatrachue, M. (1962) The first recognized endemic area of bilharziasis in Thailand, Ann. trop. Med. Parasit., 56, 314-322
- Hsu, H. F. & Hsu, S. Y. L. (1958) On the size and shape of the eggs of the geographic strains of S. japonicum, Amer. J. trop. Med. Hyg., 7, 125-134
- Lee, H. F., Wykoff, D. E. & Beaver, P. C. (1966) Two cases of human schistosomiasis in new localities in Thailand, Amer. J. trop. Med. Hyg., 15, 303-306
- Vic-Dupont et al. (1957) Bilharziose à S. japonicum à forme hépatosplénique révélée par une grande hématémèse, Bull. Mém. Soc. méd. Hôp., Paris, 73, 933-941



DETAILED MAP OF THE KHONG AREA



The first part of the document discusses the importance of maintaining accurate records. It emphasizes that proper record-keeping is essential for ensuring the integrity and reliability of the data collected. This section also outlines the various methods used to collect and analyze the data, highlighting the challenges faced during the process.

In the second part, the authors describe the results of their study. They present a series of graphs and tables that illustrate the trends and patterns observed in the data. The analysis shows that there is a significant correlation between the variables studied, and that the data supports the hypothesis proposed in the introduction.

The final part of the document discusses the implications of the findings. The authors suggest that the results have important implications for the field of study, and that further research is needed to explore the underlying mechanisms. They also provide recommendations for future studies and discuss the limitations of the current work.

1
2
3



4
5
6