



ON THE QUESTION OF HUMAN INFECTION BY NEMATODES
OF THE FAMILY MERMITHIDAE
(DORYLAIMIDA: ADENOPHORA)

by

George O. Poinar, jr
Division of Entomology and Parasitology, University of California,
Berkeley, California 94720



ABSTRACT

Certain representatives of the nematode family Mermithidae (Dorylaimida: Adenophora) have been reported as accidental parasites of man. Since specific mermithids are now being released for the biological control of insects, the above reports are disturbing. The present study reviews all cases that could be found of alleged mermithid parasitism of man and discusses them in relation to nematode identification and evidence of actual parasitism. In conclusion, human infection by mermithid nematodes cannot be answered at this time and should be accepted as a fact when proven experimentally or when parasites are found developing in situ.

INTRODUCTION

Members of the Mermithidae (Dorylaimida: Adenophora) commonly parasitize insects, although spiders, crustaceans, leeches and molluscs are also attacked. Even with this extended host range, it is surprising to learn that mermithids have been also cited as parasites of man and are the only group of entomogenous nematodes to be reported as such. In their catalogue of worms reported for man, Stiles & Hassall (1926) list the mermithid, Agamomeris restiformis (Leidy) as occurring in the urethra and being passed in the urine of man. Neveu-Lemaire (1936) mentioned that A. restiformis had been found twice in man and considered these cases as accidental parasitism. In regards the same parasite, Foster (1963) stated "although physiological conditions in man differ profoundly from those found in its usual insect hosts, the parasite may establish itself and remain within the body for long periods".

Some species of mermithids are now being mass produced and used in nature as biological control agents, and others offer much potential in this direction and are likely to be used similarly in the future. As a consequence, the question of human infection becomes even more acute since with a wider distribution, could mermithids become a health hazard?

The purpose of this study is to critically review all known cases of alleged mermithid parasitism of man, including a re-examination of the original specimens when possible, and to discuss them in relation to nematode identification and evidence of actual parasitism. Two new cases are also presented.

Abbreviated title: human infection by Mermithidae

Index key words: Mermithidae, entomogenous nematodes, human parasitism, accidental parasites.

The issue of this document does not constitute formal publication. It should not be reviewed, abstracted or quoted without the agreement of the World Health Organization. Authors alone are responsible for views expressed in signed articles.

Ce document ne constitue pas une publication. Il ne doit faire l'objet d'aucun compte rendu ou résumé ni d'aucune citation sans l'autorisation de l'Organisation Mondiale de la Santé. Les opinions exprimées dans les articles signés n'engagent que leurs auteurs.

MATERIALS AND METHODS

Specimens and assistance for this study were received from the following persons: S. Prudhoe, Department of Zoology, British Museum of Natural History, London, who loaned the material described by Baylis (1927); L. A. Leon, Laboratorio de Parasitologia y Medicina Tropical, Quito, Ecuador, who supplied a previously unrecorded mermithid allegedly passed by a boy; W. R. Nickle, Plant Nematology Laboratory, Beltsville, Maryland, sent a previously unrecorded mermithid allegedly passed by a human; A. Morgan Golden, Plant Nematology Laboratory, Beltsville, and Gordon W. Vacura, curator, Medical Museum, Washington D.C., attempted to locate the type material of Agamomermis restiformis (Leidy); and S. L. H. Fuller, Academy of Natural Sciences, Philadelphia, Pennsylvania, attempted to locate Agamomermis hominis oris (Leidy).

All specimens were either cleared in lactophenol or processed to glycerin before examination.

RESULTS

All cases of mermithid nematodes allegedly passed by humans that were located by the author are discussed below in chronological order. An attempt was made to examine the diagnostic characters of each specimen and confirm its identity.

1. Agamomermis hominis oris (Leidy) = Filaria hominis oris Leidy 1850. Location - Described from a single preserved specimen labelled "obtained from the mouth of a child" (Leidy, 1850). Description - Body thread-like, white, opaque; length 140 mm; greatest width 0.38 mm; head round; width at head 0.101 mm; tail obtuse, width 0.317 mm; tail bearing a spike 0.050 mm long and 0.013 mm wide at base. Comments - Although the type specimen has been lost or misplaced and is not available for study (Fuller, personal correspondence, 1973; Stiles, 1907, indicated that it probably had been destroyed), the description fits that of a mermithid. Also, Leidy (1875) later identified some mermithids collected from an apple as Mermis (= Hexamermis) acuminata and stated that they could have been the same species as A. hominis oris. He also collected a similar mermithid from codling moth larvae which explains how a child might have encountered the parasite. Stiles (1907) also reported finding mermithids from apples. Thus, although we cannot definitely reconstruct the circumstances surrounding the presence of a mermithid in a child's mouth, it is possible that it came from an insect that was ingested by the child directly or indirectly (through eating infested fruit).

2. Agamomermis restiformis (Leidy) = Filaria restiformis Leidy (1880). Location - Said to have been removed from the urethra of a man in the United States. Description - (After Leidy, 1880) (Figs 8 and 9). Vivid red in colour and very active when collected; 66 cm long, greatest width 1.5 mm; caudal end curved, bluntly rounded; lacking an anus or genital aperture. Mouth a terminal pore without lips, papillae or any kind of armature; pharynx cylindrical, opening into a straight cylindrical intestine which apparently ends in a blind pouch; body width at neck region 0.375 mm, width at beginning of intestine 0.625 mm; width at curved caudal extremity 1.5 mm; length of oesophagus 1.125 mm. The following supplementary description is taken from Stiles (1908) (Figs 7 and 10). Cuticle composed of several concentric layers, 32 μ thick on anterior portion and 48 μ thick in tail region; head bearing 6 papillae; pharynx represented by a cuticular tube, 17-26 μ in diameter, surrounded by pharyngeal tissue reaching 130 μ in diameter; pharyngeal tube meets a blind sac which is directed anteriorly; no genital organs were observed; cross sections show 6 muscle fields separated by longitudinal chordes. Comments - Unfortunately, the type specimen of A. restiformis could not be located in the Armed Forces Institute of Pathology Medical Museum. Apparently the specimen was either lost or misplaced as a result of many physical moves of the museum (Vacura, personal correspondence, 1973). Thus, any interpretations on the identity of this nematode have to be based on the published accounts of Leidy (1880) and Stiles (1908). As the latter author mentioned, the presence of 6 longitudinal chordes, cross fibres in the cuticle, cuticular lining of the pharynx and a suggestion of a blind intestinal sac are characters found in members of the Mermithidae. However, the amount of tissue surrounding the pharyngeal tube and the association of this tissue with the intestine suggests that the specimen might belong to another nematode

group. Also, the large size (66 cm) would certainly be a record for the mermithids, although it lies within the realm of possibility. The only known species that comes near to attaining this size in the United States is Mermis nigrescens Duj (= subnigrescens Cobb) which reaches 16.3 cm (Cobb, 1926) and possesses a pair of lip papillae clearly lacking in the species under question (compare Figs 3 and 7). Leidy (1880) also stated that the pharynx opened into a straight cylindrical intestine, a character not mentioned in the redescription of Stiles (1908). However, in a juvenile mermithid of this size, the pharynx (= stichosome) and intestine are separate and not connected with one another.

Assuming that the information given by the patient is correct (an assumption questioned by Stiles, 1908, who stated, "Further, the idea that an error has occurred in interpreting this worm as a parasite of man seems to gain support, for it would be exceedingly difficult to explain the presence of a Mermithidae in the bladder"), there is the question of the parasite's identity. Although Stiles (1908) considered this specimen as a mermithid, Leidy (1880) did not, and neither description gives conclusive evidence that the worm belongs to this family. Could it possibly have been a juvenile of the giant kidney worm, Dioctyophyma renale (Goeze)? This latter nematode occurs in the kidney and sometimes other organs of both wild and domestic animals throughout the world and at least 10 cases have been reported from humans. The parasites are reddish in colour and the males range from 14 to 45 cm in length and females from 20 to 100 cm (Levine, 1968). The cuticle is striated and the pharynx long and narrow. The worms may attempt to escape down the ureter and produce acute uremic poisoning or may succeed in escaping from the urethra causing the urine to contain blood and pus (Faust, 1929). These symptoms are almost identical to the following that were described from the patient who passed A. restiformis. "Previous to its passage, his urine was of a milky hue and some time subsequently of a yellow cast and slightly tinged with blood and mingled with mucus" (Leidy, 1880). Thus, it seems possible that A. restiformis may have been a juvenile of the giant kidney worm.

3. Mermithid from a woman in Australia (Baylis, 1927). Location - ". . . said to have been passed by a woman thought to be suffering from uterine cancer, whether per vaginam, rectum or urethram, not stated" (after Baylis, 1927). Description - After Baylis (1927). Pinkish flesh colour, about 56 cm long; greatest width about 1 mm. The present author examined the specimen, agrees that it is an immature mermithid and adds the following supplementary description (Figs 1 and 2): lip papillae absent; 6 head papillae; cross fibres in the cuticle; pharyngeal tube present, relatively wide as compared to other mermithids; amphids not distinct; a minute spike on the tip of the tail; protein platelets present in the pseudocoelom (from 41-77 μ in diameter) and similar in shape and form to those observed in Hydromermis sp. (Poinar et al., 1970). Comments - Unfortunately the data surrounding its occurrence are rather meagre and definite conclusions as to its parasitic role in humans cannot be made.

4. Mermithid from the urethra of an alcoholic individual. Location - Neveu-Lemaire (1936) mentioned a case where a mermithid (designated as A. restiformis) was found in the urethra of an alcoholic individual, similar to the case cited previously. Neveu-Lemaire considered it to be a case of accidental parasitism; however, further details and a description are lacking.

5. Mermithid said to occur in the intestine of a child. Location - A nematode identified as Agamomermis hominis by Leon (1946) was collected from the faeces of a five-year-old girl from Ibarra, Ecuador. She had just been given a treatment for Ascaris. Description - body whitish, 210 mm long; greatest width 0.8 mm; width 1 mm from the head, 0.15 mm; width 1 mm from the tail end, 0.5 mm; pharyngeal tube 0.8 mm long and 0.011 mm in diameter; the trophosome extends to 0.300 mm from the head end; cuticle with fine cross fibres. Comments - Leon's description fits that of a mermithid nematode. Leon considered the worm as an accidental parasite in the intestine of the child and suggested that it was ingested with food or water. It is not known if postparasitic juvenile mermithids can survive the conditions found in the digestive tract of warm-blooded vertebrates; however, if the data is correct, it would suggest that they can. Whether it was parasitic or simply maintained itself in this habitat remains unanswered.

6. A mermithid from a Belgium Congo girl (Watson, 1960). Location - An immature mermithid (Agamomermis) was recovered from the urethra of a 10-year-old girl who had suffered violent hypogastric pain during the preceding night. This case was briefly mentioned by Watson (1960) in an appendix of his book. There is no description or further information.

7. A mermithid recovered from urine. Location - The specimen, which the author received from Beltsville, Maryland, was simply labelled "from urine" and evidently was sent to B. G. Chitwood after being collected by Dr Hoffman in Puerto Rico on 5 August 1932. It had been labelled "Hexameris hoffmani n. sp." on the slides, but since a published description never appeared, the name is invalid. Description - (Fig. 4) Length 56 mm, greatest width 0.336 mm, no lip papillae, 6 head papillae, no cross fibres in the cuticle, minute scar on the tip of the tail. The specimen is a postparasitic juvenile mermithid surrounded by a loose cuticle. A small rudimentary genital opening indicated that the specimen was either an immature male or intersex. Comments - Again, the brevity of information concerning the location of the worm makes it impossible to state whether it had spent a period of time in the human body.

8. Mermithid reportedly passed from the intestine of a child. Location - From the faeces of a boy in Ibarra, Ecuador; collected on 26 May 1942. Description - (Figs 5 and 6) A juvenile mermithid; length 210 mm; greatest width 0.507 mm; width at head 1 mm from tip, 0.288 mm; width at tail 1 mm from tip 0.480 mm; pharynx extends over 6 mm from the head end and the diameter of the pharyngeal tube is 0.016 mm; tip of trophosome to head end 0.516 mm; no lip papillae, 6 head papillae; cuticle with faint cross striations; no tail spike; trophosome extends almost to tip of tail. Comments - This mermithid was obtained from Dr Leon of Quito, Ecuador. Although the conditions under which it was found were very similar to the published account of A. hominis (Leon, 1946), it is clearly different and was collected two years earlier than the above-mentioned case.

DISCUSSION

In most of the cases described here, the data pertaining to the occurrence of the parasite is such that it cannot be ascertained if human parasitism actually occurred. In Cases 5 and 8, for instance, the worms were obtained from faeces and could simply have been ingested and passed unharmed through the digestive tract of the patient. Or they could have emerged from parasitized sarcophagus insects that had visited the faeces. The latter explanation could also account for the presence of mermithids in urine (Case 7 and possibly Cases 4 and 6 if the worms were found in the urine and assumed to have been passed from the urethra). A parasitized insect could have fallen into the toilet bowl or free-living mermithids could have already been in the area. A case illustrating the latter possibility was mentioned by Prudhoe (1973, personal correspondence) regarding a small boy who was said to have passed two mermithids (later identified as adult females of Mermis nigrescens). Apparently the boy had urinated among some bushes and the nematodes were found in the area he had covered. The boy's mother concluded he had passed them while urinating. This occurred in June, when the females of M. nigrescens are found near the surface of the soil.

Only in Case 2, where the description of the location of the parasite in the patient was rather extensive and detailed, would there be less chance of an error in observation. However, in this case, there was a question regarding the identity of the parasite which cannot be resolved until the specimen is relocated and re-examined. Even then, it may be in such a condition that a complete identification is impossible.

Needless to say, the question of accidental human infection by mermithid nematodes cannot be definitely answered at this time and should only be accepted as fact when proven experimentally or when parasites are found developing in situ in the human organism.

Preliminary studies regarding the establishment of the mermithid, Reesimermis nielseni Tsai and Grundmann, in mice and rats have been conducted (Ignoffo et al., 1974). Suckling and adult mice and adult rats were subjected to either per os, intranasal, intraperitoneal or dermal challenge of the infective stages of R. nielseni. Body weight gain and histological examination of treated animals were no different from the control lot. These initial experiments indicate that the infective stages of R. nielseni cannot become established in rats or mice; however, similar and additional tests with other mermithids would be worthwhile.

Before concluding this topic, a few words should be said about another group of worms that are similar to mermithids in superficial aspects and in their ability to parasitize insects. These are the hair worms of the order Nematomorpha which also have been reported from humans (Watson, 1960). Although sometimes resembling mermithid nematodes in shape and size, hair worms are distinctly different and should not be confused with the latter. Regarding superficial differences, hair worms generally range from light to dark brown in colour and possess a very thick body wall. Mermithid nematodes, in contrast, are generally white in colour (sometimes pink or light green) and possess a transparent, soft body wall. Most reports of hair worms from humans cite the parasites as occurring in the urogenital or alimentary tract and unfortunately are as open to question as those of the mermithids.

REFERENCES

- Baylis, H. A. (1927) Notes on two gordiids and a mermithid said to have been parasitic in man, Trans. roy. Soc. trop. Med. Hyg., 21, 203-206
- Cobb, N. A. (1926) The species of Mermis, a group of very remarkable nemas infesting insects, J. Parasit., 13, 66-72
- Faust, E. C. (1929) Human Helminthology, Zea & Febiger, Philadelphia, 616 pp.
- Foster, R. (1963) Infestation of Glossina palpalis R.-D. 1830 (Diptera) by larval Mermithidae Braun 1883 (Nematoda) in West Africa, with some comments on the parasitization of man by the worms, Ann. trop. Med. Parasit., 57, 347-358
- Ignoffo, C. M., Petersen, J. J., Chapman, H. C. & Novotny, J. F. (1974) Lack of susceptibility of mice and rats to the mosquito nematode Reesimermis nielseni Tsai and Grundmann, Environmental Entomology (In press)
- Leidy, J. (1850) Descriptions of three Filariae. Proceedings of the Academy of Natural Sciences of Philadelphia, 5, 117-118
- Leidy, J. (1875) Notes on some parasitic worms. Proceedings of the Academy of Natural Sciences of Philadelphia, 27, 14-16, 17-18, 400
- Leidy, J. (1880) On a filaria reported to have come from a man. Proceedings of the Academy of Natural Sciences of Philadelphia, 32, 130-131
- Leon, L. A. (1946) Cuarto caso de infeccion humana por Agamomermis, Revista de Medicina Tropical y Parasitologia Bacteriologia, Clinica y Laboratorio Habana, 12, 25-26
- Levine, N. D. (1968) Nematode Parasites of Domestic Animals and of Man, Burgess Publishing Company, Minneapolis, 600 pp.
- Neveu-Lemaire, M. (1936) Traité d'helminthologie médicale et vétérinaire, Vigot Frères, Paris 1515 pp.
- Poinar, G. O. jr, Leutenegger, R. & Thomas, G. M. (1970) On the occurrence of protein platelets in the pseudocoelom of a nematode (Hydromermis sp.; Mermithidae), Nematologica, 16, 348-352
- Stiles, C. W. (1907) The zoological characters of the roundworm genus Filaria Mueller, 1787, with a list of the thread worms reported for man, Bulletin of the Hygienic Laboratory, 34, 31-51
- Stiles, C. W. (1908) A reexamination of the type specimen of Filaria restiformis Leidy, 1880, = Agamomermis restiformis, Bulletin of the Hygienic Laboratory, 40, 19-22
- Stiles, C. W. & Hassall, A. (1926) Key-catalogue of the worms reported for man, Bulletin of the Hygienic Laboratory, 142, 1-196
- Watson, J. M. (1960) Medical Helminthology, Baillière Tindall & Cox, London, 487 pp.

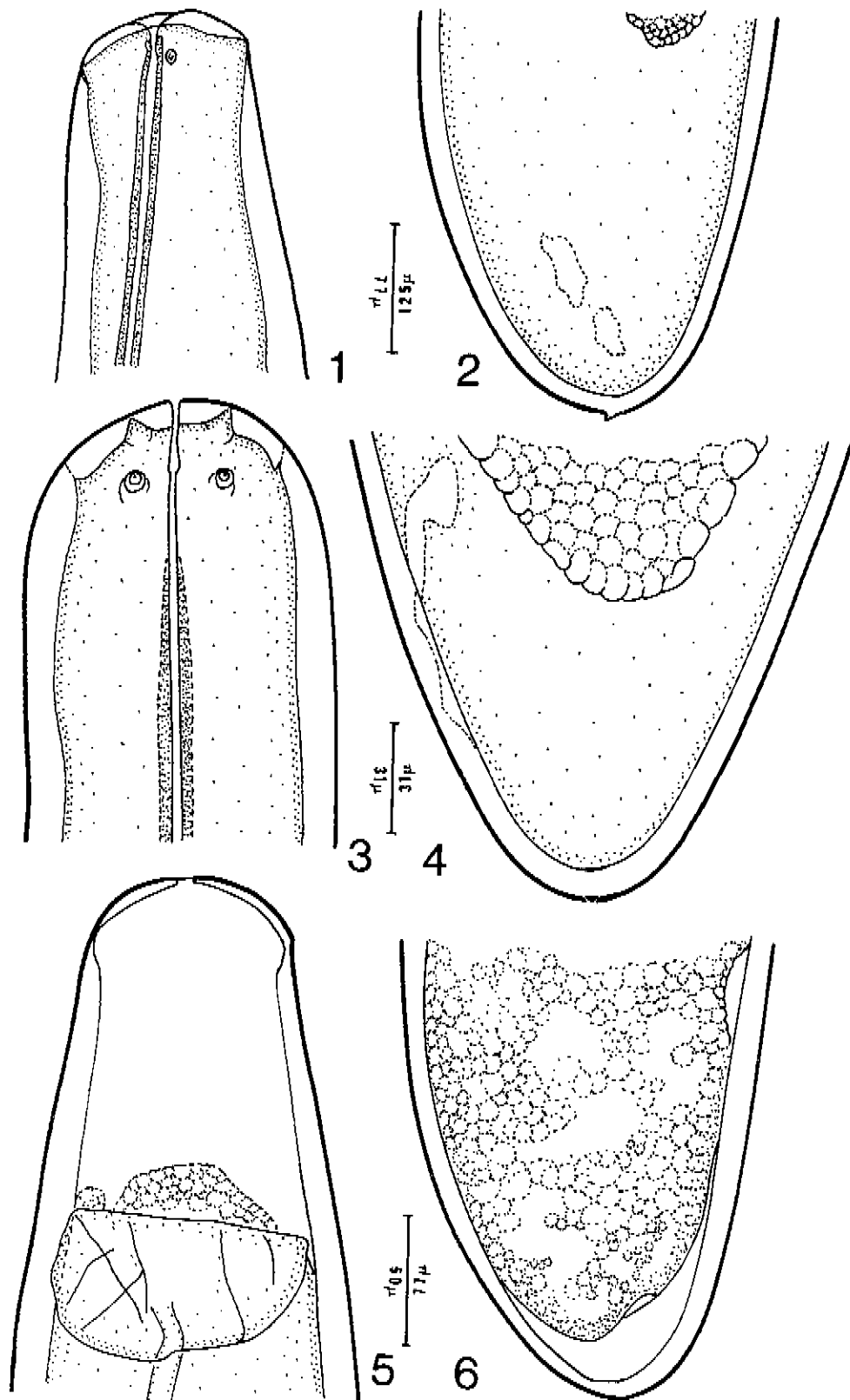
FIGURES

Figs 1-6. Mermithids thought to have been passed by humans.

- Fig. 1. Head of a mermithid supposedly passed by a woman in Australia.
- Fig. 2. Tail of a mermithid said to have been passed by a woman in Australia.
- Fig. 3. Head of a post-parasitic juvenile female Mermis nigrescens reared from an insect.
- Fig. 4. Tail of a mermithid collected from "urine" in Puerto Rico.
- Fig. 5. Head of a mermithid supposedly passed in the faeces of a child in Ecuador.
- Fig. 6. Tail of a mermithid said to have been passed in the faeces of a child in Ecuador.

Figs 7-10. A copy of one of Stiles' (1908) figures from his study on the redescription of Agamomermis restiformis (Leidy) (slightly modified).

- Fig. 7. Entire specimen of A. restiformis (approximately natural size; no scale given in original figure).
- Fig. 8. Leidy's drawing of the head of A. restiformis copied by Stiles (1908).
- Fig. 9. Leidy's drawing of the tail of A. restiformis copied by Stiles (1908).
- Fig. 10. Anterior end of A. restiformis (after Stiles, 1908) (c - cuticle; e - excretory pore (?); i - intestine; l - lumen of pharynx; p - papilla; pt - pharyngeal tube; t - tissue surrounding pharyngeal tube).



FIGS 1-6

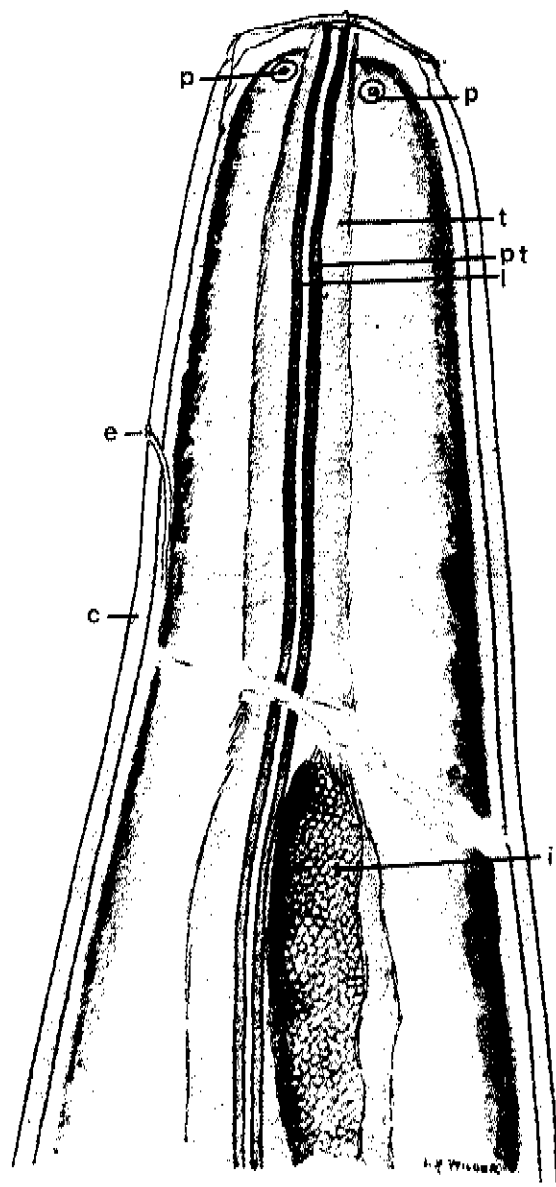


7



8

750µ



p

t

p

t

pt


e

c

i

200µ

10



9

1500µ

FIGS 7-10

* * *